



Clinical presentation and diagnosis of calcinosis circumscripta in a one-year-old male Caucasian dog

OO Ola^{1*}, MO Tijani¹, TA Jarikre¹, OS Olaifa¹, OO Alaka¹, OG Ohore¹, AA Usman¹, JO Ajayi² & BO Adeoye³

1. Department of Veterinary Pathology, Faculty of Veterinary Medicine, University of Ibadan, Nigeria
2. Federal College of Animal Health and Production Technology, Ibadan, Nigeria
3. Department of Pharmacology and Toxicology, Faculty of Veterinary Medicine, University of Ibadan, Nigeria

*Correspondence: Tel.: +2348066567384; E-mail: olawumi.olawale@gmail.com

Copyright: © 2025 Ola et al. This is an open-access article published under the terms of the Creative Commons Attribution License which permits unrestricted use, distribution, and reproduction in any medium, provided the original author and source are credited.

Abstract

Calcinosis is characterized by the deposition of calcium salts in or under the skin, often manifesting as firm, white plaques or masses. This condition can present in various anatomical locations and is commonly associated with inflammation and discomfort. When this deposition occurs in the dermis and subcutaneous tissues due to hyperadrenocorticism, dystrophic or idiopathic calcification, it is termed calcinosis cutis. On the other hand, when the calcification occurs as a result of repetitive trauma or at the site of buried sutures, it is termed calcinosis circumscripta and is usually based on the pattern of distribution. Accurate diagnosis and management are essential for improving the quality of life in affected animals. In this case, we report a diagnosis of calcinosis circumscripta in a 1-year-old male Caucasian dog presented with a firm, non-ulcerated, solitary mass on the right lateral proximal femur, which had been preceded by an abscess a year prior. Gross examination revealed a hard, cutaneous mass with multiple mineralized structures within thick fibrous connective tissue. The mass was surgically excised and histopathologically evaluated. Microscopic examination showed variably sized circumscribed lakes of basophilic granular material surrounded by fibrous connective tissue without inflammatory cells, indicating Stage I calcinosis circumscripta. The findings suggest a dystrophic form of calcification, possibly enhanced by the active calcium metabolism in the rapidly growing dog and the history of a previous unresolved injection site abscess. This diagnosis was supported by the histopathologic findings and confirmed using Von Kossa stain as one of the special stains to demonstrate the calcium deposits. The case underscores the importance of detailed examination, histopathological and histochemical evaluation in the diagnosis and management of calcinosis circumscripta in Veterinary practice.

Publication History:

Received: 09-10-2024

Revised: 20-11-2024

Accepted: 26-11-2024

Keywords: Calcinosis cutis, Calcinosis circumscripta, Dystrophic calcification, Von Kossa stain, Histopathology

Introduction

Calcinosis is defined as calcium deposition in tissues or under the skin (Abeloos et al., 2023). The term calcinosis cutis is used when the deposition affects

the dermis and subcutaneous tissues (Moraes et al., 2021). This condition can manifest in various anatomical locations, such as the scrotum, tarsal

joints, conjunctiva, cutaneous and subcutaneous tissues leading to different clinical presentations (Abeloos *et al.*, 2023). Calcium salts exist as carbonates or phosphates, but are mostly comprised of hydroxyapatite (Kabilan *et al.*, 2023). The mineralization process involves the deposition of calcium in the dermis or lamina propria of other tissues, resulting grossly in firm, white plaques or masses that can be clinically asymptomatic or associated with inflammation and discomfort (Muller *et al.*, 2011). While the exact aetiology of calcinosis cutis remains unclear in many cases, it is often attributed to dystrophic, metastatic, iatrogenic or idiopathic calcification (Muller *et al.*, 2011).

It is essential to consider differential diagnoses such as demodicosis, acral lick dermatitis, furunculosis and provide appropriate management to improve the quality of life for affected animals (Lee *et al.*, 2016). Calcinosis circumscripta is a variant of calcinosis cutis which commonly occurs in young dogs but can sometimes be found also in older dogs (Watanabe *et al.*, 2014). It is otherwise known as tumoral calcinosis, pseudogout, and lipocalcinosis. Calcinosis circumscripta most commonly occurs on pressure points or areas of trauma and bony prominences, especially in young, growing dogs with enhanced calcium and phosphate metabolism (Ardolino *et al.*, 2012). Histologically, calcinosis circumscripta is distinctive, with large, irregular foci of basophilic granular deposits that elicit a marked foreign body response and fibrosis (Robin *et al.*, 2021). They are usually with multiple nodular mineral deposits in the dermal layer of the skin (Watanabe *et al.*, 2014). It is known to affect large breeds of dogs like German shepherds, Rotweillers, Labradors and Caucasians, usually younger than two years old (Kabilan *et al.*, 2023). The lesions are usually solitary, affecting most times the hind limb and surgical excision is the treatment or management of choice (Lee *et al.*, 2016).

Case Presentation

Case history

This is a case of a 1-year-old male Caucasian dog presented with a complaint of limping. On examination, a firm, solitary mass was observed on the right lateral proximal femur. A year prior to the presentation, an abscess had been observed on the same spot and was treated by the referring Veterinarian. All haematological and serum chemistry analyses were normal for the dog. The mass was surgically excised and sent to the Department of Veterinary Pathology, University of Ibadan for histopathological evaluation. The diagnosis was to

assist allay the fear of a possible neoplastic condition. The sample was formalin-fixed. Grossly, the excised tissue was observed to be a hard, cutaneous mass that measured 4x2.5x2 cm with rough surfaces. It was difficult to cut and was gritty. The cut surface revealed multiple, variably sized 1x1-2-3.5mm, whitish/chalky, mineralized structures multifocally distributed and enmeshed within thick fibrous connective tissue (Plate I). The mass was trimmed and processed for histopathological evaluation. The sample was routinely processed and embedded in a paraffin block. The block was trimmed, sectioned and stained with haematoxylin and eosin. Microscopic examination of the prepared slide revealed an intact epidermis and within the dermis and subcutis were variably sized, circumscribed lakes of basophilic granular material surrounded by thick bands of fibrous connective tissue (Plate II). Inflammatory cells were absent. Based on the absence of inflammatory cells, this case was diagnosed as Stage I type of calcinosis circumscripta. This diagnosis was supported by histopathologic findings that suggested a process of dystrophic calcification and degeneration and also by the use of Von Kossa to specifically indicate the calcium deposits in affected tissues (Plate III).

Discussion

In Veterinary medicine, the diagnosis of calcinosis cutis in dogs requires detailed examination for accurate identification (Muller *et al.*, 2011). Here, we present a case of calcinosis circumscripta diagnosed following histopathological evaluation of a referred nodular swelling excised from the right lateral proximal femur of a 1-year-old Caucasian dog. This process can be seen secondary to / or in association with, a number of disorders involving imbalance in calcium metabolism. Metastatic calcification describes calcium salts that precipitate within normal tissues as a consequence of underlying systemic calcium or phosphorous imbalance (Watanabe *et al.*, 2014). This is most often seen in dogs with impaired renal function, but has also been reported in systemic blastomycosis and paecilomycosis (Watanabe *et al.*, 2014). Iatrogenic calcinosis cutis occurs secondary to percutaneous absorption or injection of calcium-containing products into the skin (Ardolino *et al.*, 2012). Dystrophic calcification usually occurs as a result of local tissue injury and is seen most commonly in dogs with iatrogenic hyperglucocorticism or endogenous hyperadrenocorticism (Ardolino *et al.*, 2012), but has also been reported in association with systemic

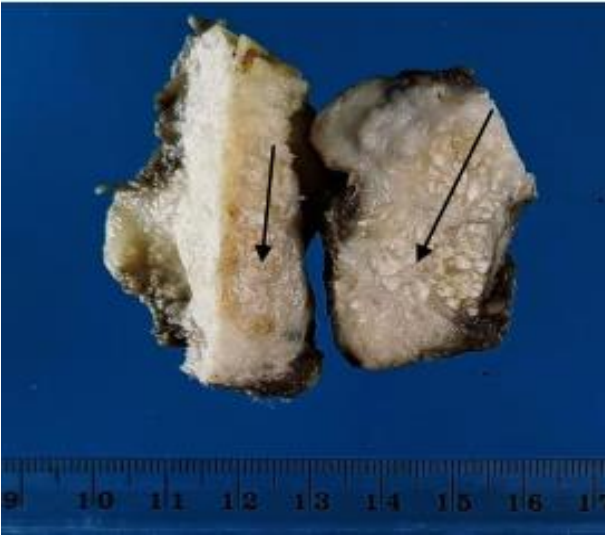

Plate I: Cut surface of cutaneous mass showing multiple whitish calcified plaques (black arrows)

disease (e.g. leptospirosis). Furthermore, conditions causing inflammation in the skin, such as follicular cysts, foreign body granulomas, interdigital pyoderma, demodicosis or pilomatrixomas, or those that after trauma results in inflammation, degeneration or necrosis, have also been reported to be associated with dystrophic calcification and ossification (Gençcelep *et al.*, 2018). Idiopathic calcification affects healthy soft tissues (Gençcelep *et al.*, 2018; Sabater *et al.*, 2016).

Both dystrophic and idiopathic calcification can occur without systemic calcium-phosphorus imbalances (Lee *et al.*, 2016). Dystrophic calcification is thought to be driven by local cytokine and growth factor release, creating a favourable microenvironment for intracellular and extracellular matrix mineralisation (Gençcelep *et al.*, 2018). This process generally consists of two main stages: initiation and propagation, either intracellularly or extracellularly (Moraes *et al.*, 2021; Robin *et al.*, 2021; Kabilan *et al.*, 2023; Abeloos *et al.*, 2023). In the initiation phase, damaged cells lose their ability to regulate calcium influx, leading to calcium buildup in the mitochondria. During the propagation phase, these calcium accumulations in dead and dying cells serve as

as nucleation sites for further mineral deposition. Progressive layering of these deposits may result in a characteristic lamellated structure (Moraes *et al.*, 2021; Abeloos *et al.*, 2023).

This case report describes a diagnosis of calcosinosis circumscripta in a one-year-old Caucasian dog and explains the value of histopathological and histochemical evaluations in achieving a definitive diagnosis. The findings in this case suggest a dystrophic form of calcification, potentially exacerbated by the dog's active calcium metabolism and a prior unresolved abscess. Surgical excision

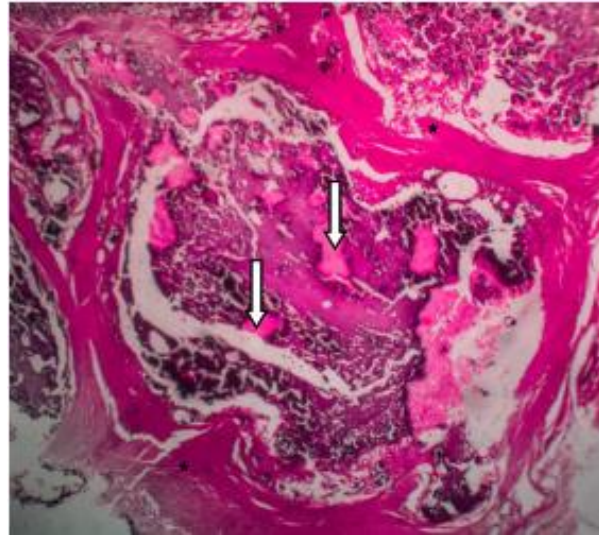


Plate II: Cutaneous mass showing abundant acellular deep purple to bluish-black calcium deposits (white arrows) surrounded by fibrous connective tissue (asterisk) in the dermis. H&E, x60

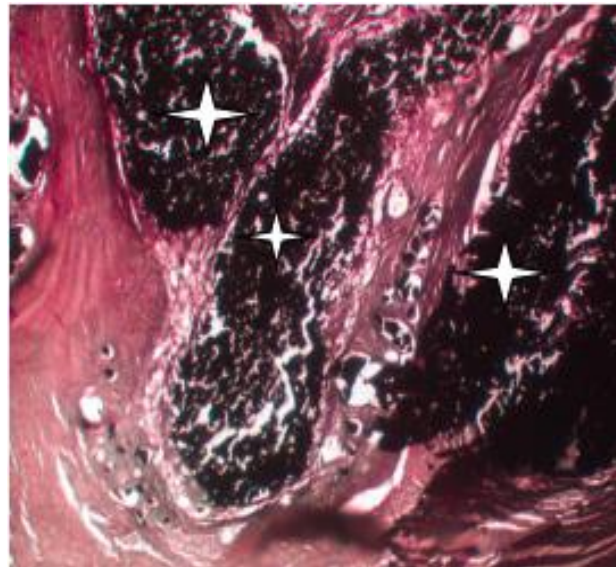


Plate III: Von Kossa stained cutaneous mass elaborating lakes of calcium deposits stained black in the dermis (white stars). x60

successfully managed the condition, with histopathology indicating Stage I calcosinosis circumscripta. Also, this case highlights the importance of early detection and prompt surgical intervention for effective management and alleviation of associated discomfort. It serves as a reminder for Veterinarians to consider calcosinosis circumscripta in the differential diagnoses of nodular skin masses and to employ comprehensive diagnostic approaches that can improve the quality of life for affected animals.

Acknowledgement

The authors thank the histopathology and histochemistry laboratory technologists of the Department of Veterinary Pathology, Faculty of Veterinary Medicine, University of Ibadan, Nigeria.

Conflict of Interest

The authors declare that there is no conflict of interest.

References

- Abeloos C, Dutton T, Denk D & Ives EJ (2023). Calcinosis circumscripta in a rabbit with recurrent cervical myelopathy. *Journal of Small Animal Practice*, doi.10.1111/jsap.13596.
- Ardolino AM, Milne BW, Patel PA, Fairhurst J & Clarke NMP (2012). Digital calcinosis circumscripta: Case series and review of the literature. *Journal of Pediatric Orthopaedics B*, doi.10.1097/BPB.0b013e3283484c15
- Gençcelep M, Yildirim S & Kuşcu Y (2018). First case report of recurrent idiopathic calcinosis circumscripta in a Kangal dog in Turkey: Clinical, radiographic and histopathological observations. *Van Veterinary Journal*, **29**(3): 185-187.
- Kabilan S, Abeykoon C, Bandarayanaka BMLN, Perera KAR & Ariyaratna H (2023). Severe calcinosis circumscripta in multiple foot pads in a 5-month-old Pomeranian puppy secondary to renal disease – A case report. *Sri Lanka Veterinary Journal*, **70**(2): 23–26.
- Lee EM, Kim AY, Lee EJ & Jeong KS (2016). Pathomorphological features of calcinosis circumscripta in a dog. *Journal of Lab Animal Research*, doi.10.5625/lar.2016.32.1.74.
- Moraes RSD, Romani AFC, Amaral AVC, Cagnini DQ, Bonfim LS & Andraschko MM (2021). Calcinosis cutis with large extension and uncommon location in a dog. *Acta Scientiae Veterinariae*, doi.10.22456/1679-9216.106730
- Muller A, Degorce-Rubiales F & Guaguère E (2011). Metastatic calcinosis (including calcinosis cutis) in a young dog with multiple urinary tract abnormalities. *Veterinary Dermatology*, doi.10.1111/j.1365-3164.2010.00919.x.
- Robin M, Raffestin S, Etienne CL, Letron IR, Regnier A & Douet JY (2021). Conjunctival calcinosis circumscripta in a dog: Treatment combining surgical resection and amniotic membrane grafting. *Veterinary Ophthalmology*, doi.10.1111/vop.12864.
- Sabater M, Carrasco DC, Huynh M, Homer-Forbes NA & Stidworthy MF (2016). Calcinosis circumscripta in the digital extensor tendon of a tawny eagle (*Aquila rapax*). *Journal of Avian Medicine Surgery*, doi.10.1647/2015-136.
- Watanabe S, Shioda T, Kobayashi K, Ishizaki S, Ito F, Fujibayashi M & Tanaka M (2014). Calcinosis cutis confined to the dermis after intravenous administration of a calcium preparation: A case report and review of the Japanese literature. *Case Report in Dermatology*, doi.10.1159/000360807.