



Polymelia, vent duplex, cloacal bursa duplex and triple caeca in a broiler chick

NJ Plang^{1*}, IJ Gosomji¹, JO Omirinde¹, SA Hena¹, IA Azeez¹, GY Gurumyen² & N Wanmi³

- ^{1.} Department of Veterinary Anatomy, Faculty of Veterinary Medicine, University of Jos, Nigeria
- ^{2.} Department of Veterinary Microbiology and Pathology, Faculty of Veterinary Medicine, University of Jos, Nigeria
- ^{3.} Department of Veterinary Anatomy, College of Veterinary Medicine, University of Agriculture, Makurdi, Nigeria

*Correspondence: Tel.: +2348069502865; E-mail: plangnaanman@gmail.com

Copyright: © 2021 Plang *et al.* This is an open-access article published under the terms of the Creative Commons Attribution License which permits unrestricted use, distribution, and reproduction in any medium, provided the original author and source are credited.

Publication History:
Received: 29-06-2020
Revised: 12-02-2021
Accepted: 16-02-2021

Abstract

Congenital abnormalities are common among avian and mammalian species. They could be partial or total drift from the normal structural organization of the organ-systems. This article is aimed at reporting the occurrence of multiple abnormalities in a 3-week-old broiler chick. Ante mortem, post-mortem, radiological and osteological investigations were carried out, to ascertain the number and form of abnormalities present in the chick. A total of four different congenital abnormalities were discovered in this chick. These include: polymelia (presence of supernumerary or accessory limb which is usually malformed); double vents (vent duplex); double cloacal bursae (bursa duplex) and triple caeca. Radiological and postmortem examinations revealed the attachment of the accessory limb to the caudal depressor muscle as a form of synsarcosis, via a tendon that originated from the deep fossa of the modified femoral head of the accessory limb. The right vent was patent whereas the left was not. The two cloacal bursae were almost the same size, while the three caeca showed slight variation in length but typical features of the avian caecum (base, middle (body) and apex) were clearly visible. However, most cases of congenital anomalies in the avian species occur as multiple defects, with the most common being polymelia. The latest finding in this report is the discovery of double cloacal bursae (bursae of Fabricius), which has not been reported in the avian species.

Keywords: Broiler chick, Cloacal bursa duplex, Polymelia, Triple caeca, Vent duplex

Introduction

Congenital malformations or abnormalities are intrinsic structural abnormalities and variations in organs, tissues and/or body systems that can occur

during embryonic development of all animal species, and maybe partial or total (Mahmood *et al.*, 2020). Polymelia is a congenital anomaly, characterized by

the presence of accessory limb(s). It occurs mostly as a result of defects in normal embryonic developments, due to various adverse influences such as teratogens, transgenes, chromosomal imbalances, infectious agents and host of other factors (Rousseaux & Ribble, 1988). "Polymelia may also be observed due to incorrect splitting of limbs or the re-absorbance of a conjoined twin back into the body" (Kim *et al.*, 2001). This congenital anomaly in the avian species could also arise from fertilization of a double yolk egg, with an incomplete differentiation into twin chicks. Polymelia has been reported in avian species and mammals (Azeez & Oyagbemi, 2013; Mahmood *et al.*, 2020). Most cases are accompanied by one or more secondary defect(s), which may vary between partial or complete duplication of lower genitourinary and gastrointestinal structures (Poullis, 2011).

The Avian hindlimbs are connected to the pelvic bone through the acetabulum in the coxocapital (hip) joint proximally, and to the tibiotarsus and fibula distally (Maierl *et al.*, 2019). However, the accessory limb may arise from various parts of the body such as vertebral column (notomelia), head (cephalomelia), thorax (thoracomelia) and pelvic bone (pygomelia) (Mahmood *et al.*, 2020).

Congenital abnormalities (especially polymelia) have been reported in birds and other species of animals, whereas double vent and triple caeca have been reported in the birds only (Hoffmann, 1968). The greatest contribution to sciences in this report is the discovery of double cloacal bursae, which has not been reported before. Therefore, this case report will contribute to the understanding of embryological disorders and teratology of the avian species.

Case Report

Case history

The attention of the Veterinarians in the Department of Veterinary Anatomy, Faculty of Veterinary Medicine, University of Jos was drawn by a farmer who discovered that one out of the hundred chicks she purchased for brooding had an extra limb. The bird was culled and placed under close monitoring, where another anomaly (duplication of the vent) was discovered. The chick was euthanized by intravenous injection of sodium pentobarbital (86mg/kg), following premedication with Ketamine (5mg/kg) through the wing vein. Radiographs of dorsoventral, ventrodorsal, and lateral views were taken at 3 milliamperes (mAs), and 55 kilovoltage potential (kVp) for 5 seconds to ascertain the

relationship of the accessory limb to the vertebral column. Post-mortem examination was carried out to assess the level of vent duplication using a calibrated iron rod, as well as to determine the site of articulation of the accessory limb. This examination led to the discovery of two additional abnormalities in the digestive and immune systems of the same bird namely: triple caeca and double cloacal bursae respectively. For further osteological assessment of the limbs, the normal and accessory limbs were subjected to chemical maceration as described by (Onwuama *et al.*, 2012), using sodium hydroxide (NaOH) at 3 % concentration.

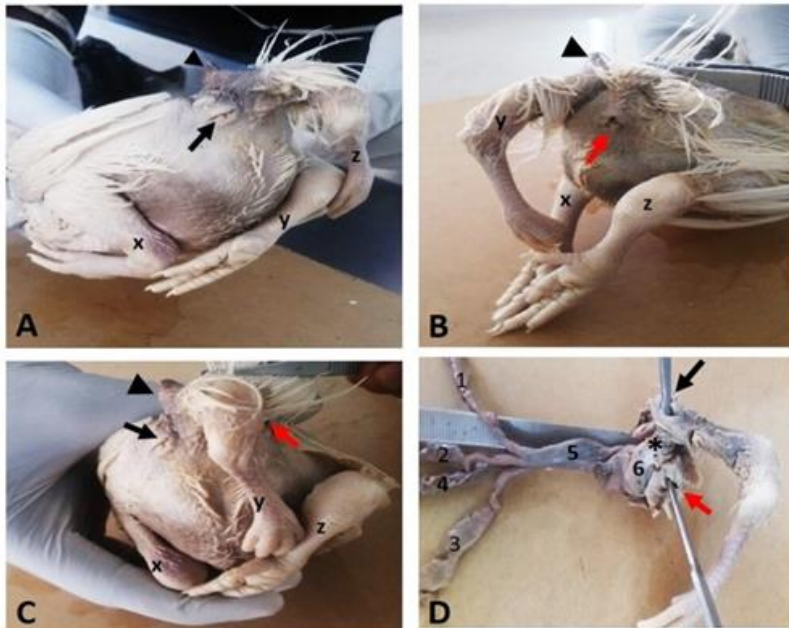


Plate I: Photograph of a three weeks old chicks. A. Left caudolateral view, B. Right caudolateral view, C. Caudal view and D. Resected caudal portion. x= left hindlimb, y=accessory limb, z=right hindlimb, black arrow=left vent, red arrow= right vent, arrow head= projection from the femur of accessory limb, asterisk=left cloacal diverticulum. 1=left caecum, 2=middle (median) caecum, 3=right caecum, 4=ileum, 5=rectum, 6=cloaca

Observation

The chick was observed to have two normal hindlimbs and an accessory limb, attached to the synsacro-coccygeal area (Plate I & IIIA). The accessory limb was short and curved

towards the right side of the body, displacing the coccygeal vertebrae right lateral (Plate IA-C & IIIA).

The right patent vent was placed ventral to the coccygeus, whereas the second vent was placed just ventrolateral to the articulation of the accessory limb in a left lateral position (Plate I). The two vents originated from a common cloaca which diverts into right and left vents. The right vent had its depth as 15mm, while the left measured 8.5 mm deep (Plate ID). The second vent (left) in this case was traced to its origin from the cloaca, a terminal portion of the rectum (large intestine). This should not be mistaken for a partial closure of the umbilical area, a remnant of the entrance through which the embryonic yolk sac and small intestine are absorbed in to the body cavity.

Osteological assessment revealed

that the femur, tibiotarsus and tarsometatarsal bones are long bones having two expanded extremities (proximal and distal epiphysis) and a shaft (diaphysis). The femur of each normal limb had on its proximal epiphysis a head, a neck and a trochanter. It also had two nutrient foramina located at mid-shaft of the bone. The normal (right and left) femoral bones measured 38.26 and 39.91 mm in length; 4.43 and 4.33 mm in width, while the femur of the accessory limb measured 36.14 mm in length and 2.40 mm in width, making it thinner and slightly shorter than the normal ones. The femur of the accessory limb was also observed to have an abnormal conical shape at its proximal extremity and a deep fossa housing the tendon of insertion with the caudal depressor muscle. It had a thin cylindrical distal extremity that blends with its shaft and lacks the nutrient foramina seen in the normal femur. The right and left tibiotarsal bones of the normal limbs had a length of 52.21 and 52.33 mm each, and a width of 3.81 and 3.84 mm, respectively. Both right and left bones had a nutrient foramen each, located at the distal third of the tibiotarsal bones. The tibiotarsal bone of the accessory limb was short and curved, measuring 15.74 mm long and 3.80mm wide.

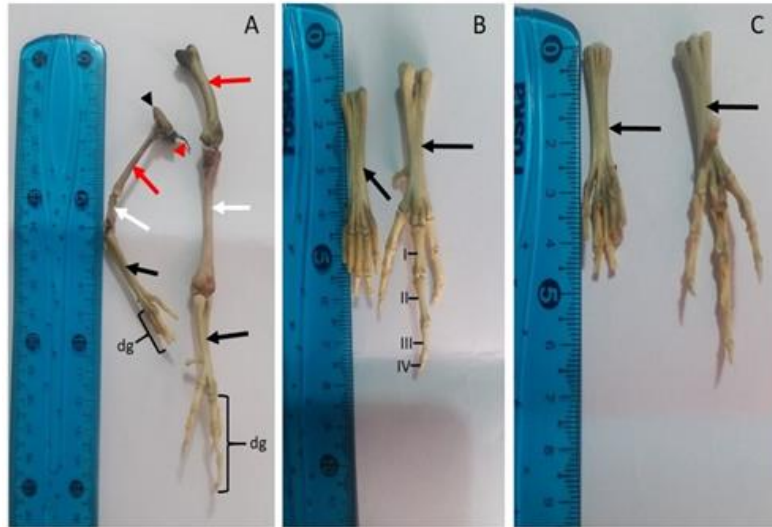


Plate II: Photograph of the bones of the accessory limb (left) and normal limb (right). A. lateral oblique view (showing the femur, tibiotarsus, tarsometatarsus and digits), B. dorsal view, C. plantar view (B and C show only tarsometatarsus and digits). dg = digits, I = first phalanx, II = second phalanx, III = third phalanx, IV = fourth phalanx, red arrow = femur, white arrow = tibiotarsal bone, black arrow = tarsometatarsal bone, red arrowhead = tendon, black arrowhead = conical projection of the head of femur (accessory limb)

It also lacks the nutrient foramen observed on the normal tibiotarsal bones. The right and left tarsometatarsal bones of the normal limbs and the accessory limb appeared to be dorso-plantarly flattened, with no much difference in their lengths and widths. The length of the accessory tarsometatarsal bone was 31.26 mm and the width was 4.97 mm, while the normal (right and left) tarsometatarsal bones measured 34.05 mm and 3.10 mm in length; 5.18 and 5.39mm in width. There were five digits (I, II, III, IV, and V) of variable sizes and a variable number of phalanges on the accessory limb. Three of the digits had up to three phalanges (with claws) and two had only a phalanx on each (without claws) (Plate II). The normal limbs had four digits (I, II, III, and IV) each (Plate II). Digits I and II had three phalanges each, III had four phalanges and IV had five phalanges (Plate II).

Radiological examination of the bird revealed no clear articulation between the accessory hindlimb and the vertebral column, but the accessory hindlimb appeared to be firmly attached to the vertebral column, through a conical bony projection (Plate III). The entire bony structures of the extra limb showed deformity, typified by unusually thin and short bones that do not conform to the bones of the hindlimb (Plate III). Although, they appeared to

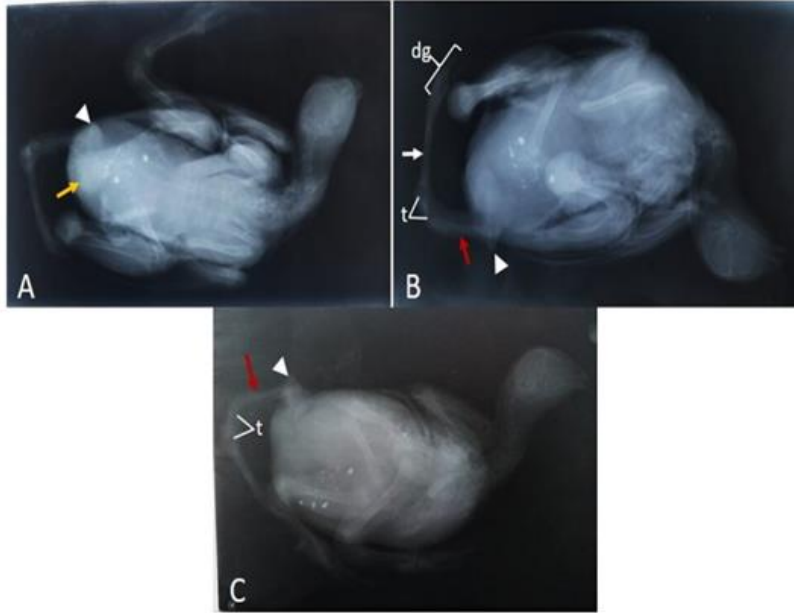


Plate III: Radiographs of a three weeks old chick. A. dorsoventral view, B. ventrodorsal view, C. lateral view. dg= digits, t= short tibiotarsal bone of the accessory limb, red arrow=femur of accessory limb, white arrow=tarsometatarsal bone, arrow head=horn-like projection of femoral head of the accessory limb

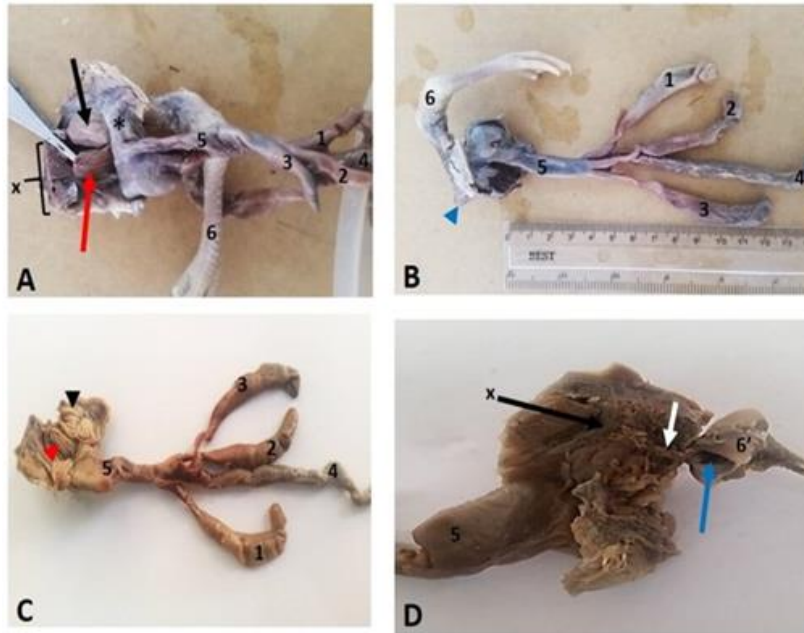


Plate IV: Photographs of the visceral structures (A, B, C, and D) of a three-week-old chick. 1=right caecum, 2=middle caecum, 3=left caecum, 4=ileum, 5=rectum, 6=accessory limb, 6'=head of the femur of the accessory limb, asterisk = left cloacal diverticulum, red arrow=right bursa of Fabricius (rbF), black arrow=left bursa of Fabricius (lbF), red arrow head= primary longitudinal fold of rbF, black arrow= primary longitudinal fold of lbF, x=caudal depressor muscle

display structures that correspond with bones of the hindlimb but are morphologically at variant with the later (Plate III). The supposed tibiotarsal bone of the extra limb is the shortest and is curved, giving it a kinked shape (Plate IIIB & C). The epiphysis and shaft of the long bones in the extra limb also showed indistinctive features (Plates IIA & III).

The postmortem dissection of the chick revealed that the accessory hindlimb does not articulate with the bony structures of the vertebral column. Instead, it articulated with the caudal depressor muscles via a tendon which exits from the deep fossa of the conical bony structure, and projects dorsolaterally to the coccygeal vertebrae (Plate IVD). Three caeca were seen at the ileorectal junction as left, median (middle), and right caeca (Plate IVA - C). The left was slightly longer than the middle, and right caeca. The individual lengths of the left, median, and right caeca measured 8.4 cm, 7.5 cm, and 7.2 cm, respectively. Each caecum was measured from the base (point of diversion from the ileorectal junction) to the apex, using digital vernier caliper. Two cloacal bursae (bursae of Fabricius) were observed ventral to the cloaca, each with typical features of the bursa of Fabricius, having longitudinal folds (Plate IVA and C). The right bursa appeared brownish, measuring 1.6cm high and 1.0cm in diameter, while the left bursa was off-white (milk cream) in color, measuring 1.2cm high and 1.1cm in diameter (Plate IVA). Each measurement was taken from the base (it origin from the cloaca) to the apex (free surface).

Discussion

The extra limb and associated defects observed in this study are similar but not the same with previous reports of double malformations (polymelia and anus duplex) in a chick (Hoffmann, 1968); Polymelia and rudimentary wings in Nigerian Nera black chicken (Azeez & Oyagbemi, 2013); Polymelia with unhealed navel in Iranian indigenous young fowl (Hassanzadeh & Rahemi, 2017); Polymelia and polydactyly in white stork (*Ciconia ciconia*) (Onmus, 2017). The curved nature and reduced number of bones of the accessory limb observed in this chick was largely due to the short irregularly curved tibiotarsal bone, which also affected the position of the tarsometatarsal bone. The five digits observed in the accessory limb instead of the normal four digits, might have occurred due to failure of resorption of the fifth digit during embryonic growth, a normal phenomenon in the avian species. The presence of three caeca and paired vent with a functional anal orifice in this chick are congenital anomalies which oppose to the largely documented literature on the normal two caeca and a single vent in most domestic poultry. These anomalies could occur as a result of partial duplication of the lower digestive tract in conjoined twins (Pourelis, 2011), a developmental malformation in the avian species. The functional implication might be in increased absorption of water and electrolytes. The cloacal bursa is functionally important in the production of B lymphocytes. Therefore, the observed cloacal duplication in this chick could be suggestive of enhancing its immune system. The duplication might also be as a result of conjoined twin malformation (Pourelis, 2011), although it has not been reported in any of the avian species.

This report has provided additional information on congenital malformations in the avian species: polymelia, vent duplex, bursa duplex, and triple caeca. Bursal duplex among other anomalies in this report, is the first report in the avian species, to the best of our literature search.

Acknowledgement

We appreciate Prof JP Chollom, Department of Mathematics, University of Jos for notifying us about the existence of this case. We wish to also appreciate Mr. Olushola Ogunleye, Victor Dangut, and Daniel Faden, for their technical support in this work.

Conflicts of Interest

The authors declare no conflict of interest.

References

- Azeez OI & Oyagbemi AA (2013). First report of polymelia and a rudimentary wing in a Nigerian nera black chicken. *Journal of the South African Veterinary Association*, doi.10.4102/jsava.v84i1.1082.
- Hassanzadeh B & Rahemi A (2017). Polymelia with unhealed navel in an Iranian indigenous young fowl. *Veterinary research forum: An International Quarterly Journal*, **8**(1):85–87.
- Hoffmann JA (1968). Doppelmissbildungen (Polymelie und Anus duplex) bei einem Hühnerküken. *Dtsch Tierarztl Wochenschr*, **75**(20): 512–514.
- Kim CS, Yeon SC, Cho GH, Lee JH, Choi MC, Won CG, Kim JG & Lee SR (2001). Polymelia with Two Extra Forelimbs at the Right Scapular Region in a Male Korean Native Calf. *Journal of Veterinary Medical Science*, **63**(10):1161–4.
- Mahmood A, Milad B, Noushin Z & Farzaneh A (2020). First Report of Polymelia in a DSH Kitten in Tehran, Iran. *Journal of Pharmacy and Pharmacology*, doi.10.17265/2328-2150/2020.02.004.
- Maierl J, Liebich HG, Köning E & Korbel R (2019). Pelvic limb (membrum pelvinum) In: *Avian Anatomy Textbook and Colour Atlas*. Second ed. S35 IQN, UK: Sheffield. Pp 69.
- Onmus O, Siki M, Gul O & Yelken O (2017). Polymelia and polydactyly in white stork (*Ciconia ciconia*). *International Journal of Avian and Wildlife Biology*, **2**(3): 70-71.
- Onwuama KT, Salami SO, Ali M & Nzalak JO (2012). Effect of Different Methods of Bone Preparation on the Skeleton of the African Giant Pouched Rat (*Cricetomys gambianus*). *International Journal of Morphology*, **30**(2): 425–427.
- Pourelis AF (2011). Developmental malformations in avian species. Manifestations of unknown or genetic etiology—a review. *Asian Journal of Animal and Veterinary Advances*, **6**(5): 401-415.
- Rousseaux CG & Ribble CS (1988). Developmental Anomalies in Farm Animals: II. Defining Etiology. *The Canadian veterinary journal = La revue veterinaire canadienne*, **29**(1): 30–40.