



Anatomy of the female reproductive system of Rusa deer (*Rusa timorensis*)

MB Mahre^{1*}, H Wahid², Y Rosnina², FFA Jesse², AZ Jaji³, NA Ojo¹, B Umaru¹ & TI Azmi³

1. Department of Veterinary Physiology, Pharmacology and Biochemistry, Faculty of Veterinary Medicine, University of Maiduguri, PMB 1069, Maiduguri, Borno State, Nigeria
2. Department of Veterinary Clinical studies, Faculty of Veterinary Medicine, Universiti Putra Malaysia, 43400 UPM Serdang, Selangor, Malaysia
3. Department of Veterinary Preclinical studies, Faculty of Veterinary Medicine, Universiti Putra Malaysia, 43400 UPM Serdang, Selangor, Malaysia

*Correspondence: Tel.: +2348095002402, E-mail: mbmahre@gmail.com

Abstract

The study aims to present baseline data on the reproductive anatomy of a poorly known tropical deer species, Rusa deer (*Rusa timorensis*). The anatomy of female reproductive system is described using seven uniparous hinds, aged between four and eight years. The various reproductive structures were studied via standard descriptive methods. There was a significant difference in the length and width of both right and left ovaries. The left ovary was slightly larger than the right ovary which indicates that it is physiologically more active. The results of the study showed that the anatomy of female reproductive system of *R. timorensis* was similar to that observed in domestic ruminants except that the uterus did not have an interconual ligament and this implies that the uterine horns are anchored in such a way that sperm deposited into only one uterine horn of the Rusa deer will be transported to the other uterine horn (interconual transport). Unlike the red brocket deer and pampas deer, the cervix of *R. timorensis* was characterized by six cervical rings projecting into the cervical canal. This feature should be taken into account when designing effective instrumentation and techniques for transcervical passage of semen during artificial insemination in this species. The results from this study have provided baseline data on the reproductive anatomy of this vulnerable species, and the knowledge generated can be useful in the development of appropriate reproductive techniques in order to increase its population in captivity and also enable easy detection of its reproductive anomalies, thus strategies to propagate and conserve the species can be established.

Keywords: Anatomy, Female, Reproductive system, Rusa deer, Timorensis

Received: 06-01- 2016

Accepted: 04-03-2016

Introduction

The Rusa deer, *Rusa timorensis*, is a species native to Indonesia and has been introduced to south-east Kalimantan, New Guinea, the Bismarck Archipelago, New Caledonia, Australia and New Zealand. It is listed as a 'vulnerable' species by the International Union for Conservation of Nature (IUCN, 2008).

Rusa deer (*R. timorensis*) farming began in 1970 in New Zealand and in 1977 in Australia (SCA, 1991). The form of *R. timorensis* farming is pastoral. In 2001, the population of farmed *R. timorensis* in Australia was 25000 deer (ANZCCART, 2001). The species is also commercially farmed in New Caledonia, Mauritius, Réunion, and Thailand (Vos,

1982) and has been farmed experimentally in Indonesia, Malaysia and Papua New Guinea (Vos, 1982; Semiadi, 2006). Farming is mainly for venison and velvet. *R. timorensis* is also a valued trophy animal in New Caledonia, New Guinea, New Zealand and Australia (Tapari, 1990).

The *R. timorensis* hinds are seasonal polyestrous breeders (Mahre *et al.*, 2012; Mahre *et al.*, 2013). Both the hinds (females deer) and the stags (males deer) attain sexual maturity at 18 months old (FAO, 1982). Under appropriate environmental conditions and proper nutrition, the major breeding activity observed in *R. timorensis* in

Malaysia is between the months of March and July (Mahre *et al.*, 2012; 2013; 2014). Successful oestrus synchronization protocol using prostaglandin analogue (PGF₂α) has been achieved in *Rusa timorensis* and all pregnancies were singleton (Mahre *et al.*, 2015). The reproductive cycle of *R. timorensis* (Mahre *et al.*, 2013) differs from that of other deer species (Asher, 2011).

Successful domestication of animals is associated with a collection of genes that confer a propensity to tameness (Clive, 2007) – a genotype that the *R. timorensis* perhaps shared with any species that could be domesticated.

The feasibility of the propagation and genetic management of several endangered species has been demonstrated, but success relies upon understanding of both male and female reproductive biology (Abdulhakeem *et al.*, 2012). Understanding the unique anatomy of the female *Rusa timorensis* reproductive system will be useful in the development of appropriate reproductive techniques in order to increase its population in captivity and also enable easy detection of its reproductive anomalies, thus strategies to propagate and conserve the species can be established. The anatomy of the female reproductive system of other deer species such as the red brocket deer (*Mazama americana*), pampas deer (*Ozotoceros bezoarticus*) and mouse deer (*Tragulus javanicus*) have been well documented (Kimura *et al.*, 2004; Ungerfeld *et al.*, 2008; Mayor *et al.*, 2012). However, no information is currently available on the anatomy of the female reproductive system of *R. timorensis*. Therefore, the aim of this study is to provide baseline data on the reproductive anatomy of a poorly known tropical deer species, Rusa deer (*Rusa timorensis*).

Materials and Methods

Ethical consideration

This study was undertaken with the approval of the Animal Care and Use Committee (reference number: UPM/FPV/PS/3.2.1.551/AUP-R141), Universiti Putra Malaysia.

Animals and management

The morphology of the female reproductive system was studied on seven uniparous hinds, aged between four and eight years. The hinds were aged using their date of birth records. The reproductive status of all the hinds (uniparous with 2 to 4 singleton pregnancies) was obtained from the farm records. Five of the hinds were killed by wild

dogs and the other two were slaughtered as described by Dahlan (2009). The hinds were raised at the Universiti Putra Malaysia deer breeding unit (2.995⁰N, 101.729⁰E). Each hind was fed 3.4 kg of commercial hays (16% crude protein), 1.1 kg of concentrates (15% crude protein) daily and fresh water was provided *ad libitum*.

Examination of the reproductive system

The reproductive tracts were examined *in situ* and then removed. The vulva, vagina, cervix, uterine body, uterine horns, oviducts and ovaries, from each animal were measured using a pair of calipers (Danyang Youngshun Tools Co. Ltd. China) and a long string. The lengths of the ovaries were measured from pole to pole and their volume calculated based on the formula, $V = \frac{4}{3} \times \pi abc$, where V is the volume of the ovary, 'a', 'b', and 'c' represent the long axis, short axis and width of ovary respectively. The length of the vulva was measured from the external vulva to the opening to the vestibule while that of the vagina was measured from the vestibule to the external cervical ostium. The cervical length was measured as the distance between the external and the internal ostia. The uterine horns were measured from the point of bifurcation to the utero-tubal junction. The length of the oviduct was taken from the uterotubal junction to the end of the fimbriae. The presence or absence of follicles and corpora lutea on the ovaries was also recorded.

Data analysis

Data were analyzed using the statistical software IBM SPSS Statistic 22. Mean and standard error of mean for each reproductive tract segment were calculated. Shapiro Wilks W test was used for normality testing. Paired Wilcoxon Signed Rank test was used to test for differences in measurements between the paired reproductive tract structures. Spearman correlation was used to test for possible influence of the number of previous pregnancies on the parameters of the reproductive tracts measured. The equation as described by Morris (1999) was applied to the parameters of the reproductive tracts measured to see if the sample size in the experiment was sufficient to show adequate replication in order to be able to detect a significant difference between animals. Differences were statistically significant when $P < 0.05$.

Table 1: Measurements of female Rusa deer reproductive structures (cm)

Structures		Left (Mean \pm SEM)	Right (Mean \pm SEM)	P-value
Ovary	Length	1.8 \pm 0.6	1.0 \pm 0.0	P < 0.05
	Width	1.0 \pm 0.9	0.5 \pm 0.2	P < 0.05
	Thickness	1.4 \pm 1.1	1.0 \pm 0.8	P > 0.05
	Weight	0.8 g \pm 0.4	0.3 g \pm 0.0	P < 0.05
Oviduct	Length	10.1 \pm 0.7	9.8 \pm 0.8	P > 0.05
Uterine horn	Length	11.0 \pm 0.5	10.6 \pm 0.7	P > 0.05
	Width	1.5 \pm 0.5	1.2 \pm 0.0	P > 0.05
Uterine body	Length	4.4 \pm 0.4		
Cervix	Length	4.4 \pm 0.8		
Vagina	Length	11.4 \pm 0.9		
Vulva	Length	4.1 \pm 0.4		

Results

Anatomy of the hind's reproductive tract

Table 1 shows the measurements of *R. timorensis* reproductive structures. There was a significant difference in the length and width of both right and left ovaries. The left ovary was slightly larger than the right ovary. There was no significant difference in oviduct and uterine horn lengths between the left and right reproductive structures. The mean lengths of the uterine body, cervix, vagina and vulva were: 4.4 \pm 0.4cm, 4.4 \pm 0.8cm, 11.8 \pm 0.9cm and 4.1 \pm 0.4cm respectively. The main reproductive anatomical characteristics of *R. timorensis* are described as follows: the internal female genital organs are located within the pelvic cavity, ventral to the rectum and dorsal to the urinary bladder. There is a pair of ovaries (Plate I) and each ovary is located close to the middle of the lateral side of the pelvic inlet. *In situ*, they lie just cranial to the external iliac artery. The ovaries are oval in shape, flattened laterally and attached closely to the walls of the uterus approximately at a level opposite the caudal end of the fused section of the uterine horns. The average volume of the left ovary is 10.6 \pm 1.5 cm³ and of the right ovary is 6.6 \pm 0.5 cm³. Follicles are seen to protrude from the surface of the left ovaries of three hinds. The surfaces of ovaries of the other hinds are smooth, indicating absence of follicular activity.

Analysis from the Spearman correlation showed that the number of previous pregnancies had no significant influence on the parameters of the reproductive tracts measured (P > 0.05). It was also found that to be able to show a 50% difference in the parameters of the reproductive tracts measured, which is what our results showed, only five animals would have been needed to be used to show a significant difference. From this we can confirm that adequate replication was made for measurement of the

parameters of the reproductive tracts of *Rusa timorensis*.

The pair of oviducts (uterine tube) which comprised the infundibulum, ampulla and isthmus are long and winded and lie in the mesosalpinx, adjacent to the ovaries. The infundibulum has irregular fimbriae along its margin, covering the ovaries. It surrounds the ovary, forming a well-developed ovarian bursa with a large opening.

The uterus consists of a small uterine body and two short uterine horns (Plate I). The uterine horns continue directly into the oviducts. The average length of the uterine body is 4.4 \pm 0.4 cm and its lumen is continuous cranially with the lumina of the uterine horns through two discrete openings. Three distinct parts of the broad ligament attached the ovaries (mesovarium), oviducts (mesosalpinx) and the uterus (mesometrium) to the abdominal wall. Unlike in the red brocket deer and mouse deer, the uterus of Rusa deer did not have an intercornual ligament.

The cervix located at the caudal end of the uterine body (Plate II) is a firm, muscular tube characterized by a constricted lumen. Longitudinal section of the cervix revealed that the lumen is narrow and convoluted, its path being formed by firm fibrous knob-like projections from the wall of the cervix (Plate III). Six circular folds (cervical rings) project into the cervical canal (Plate II). These folds vary in height and length, and are annulus. The most cranial fold is not as well developed as the other five and the numbers of cervical rings are similar between the hinds examined.

The vagina is long and wide (Plate IV). The vaginal mucosa forms longitudinal folds. The vaginal cavity extends from the caudal end of the cervix to the vestibule. The external urethral orifice marks the caudal extent of the vagina and the fornix marks the cranial extent. The vestibule extends from the external urethral orifice to the vulva.

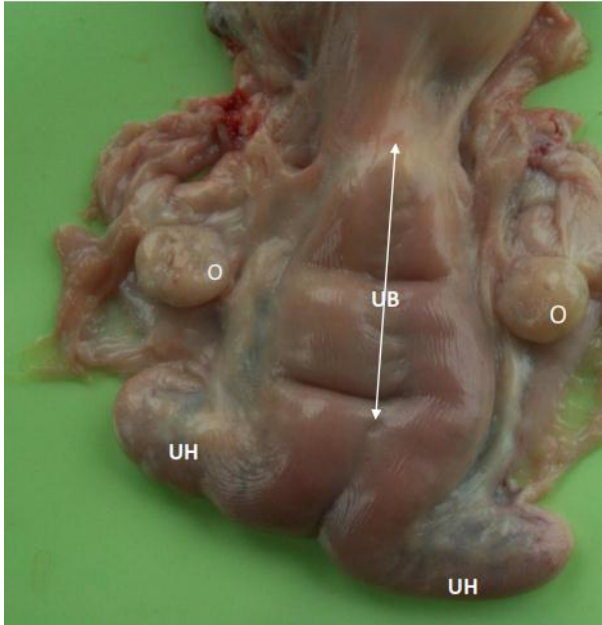


Plate I: A non-gravid reproductive tract of *R. timorensis* hind showing the paired ovaries (O), uterine horns (UH) and a uterine body (UB)

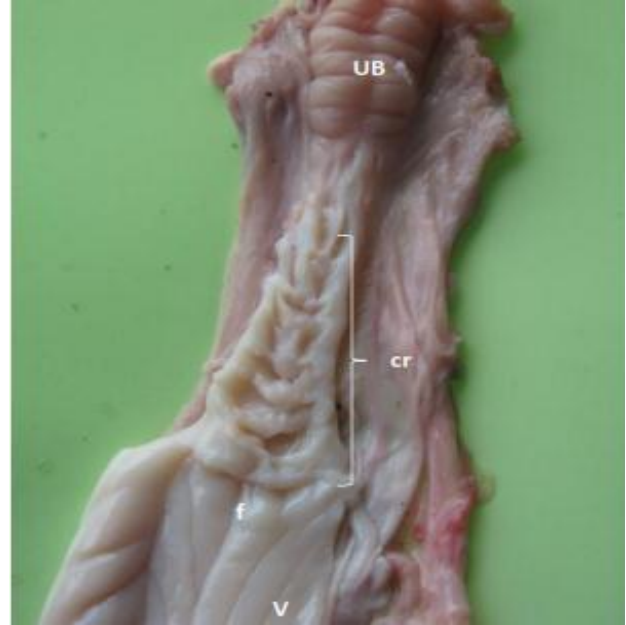


Plate II: A non-gravid reproductive tract of *R. timorensis* showing the uterine body (UB), cervix and vagina (V). Note the cervical rings (cr) and the vaginal fornix (f)

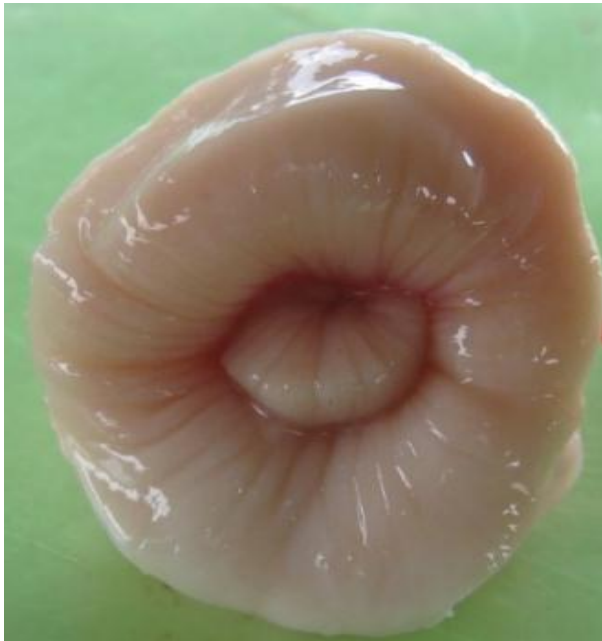

Plate III: Cervical ring projecting into the cervical canal

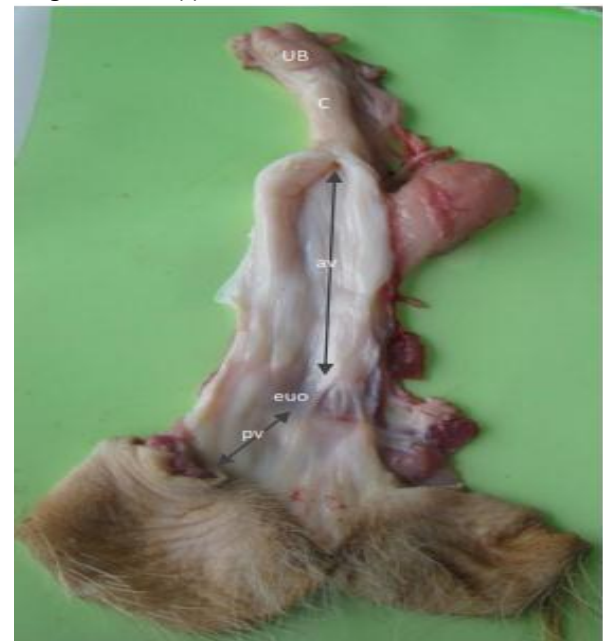

Plate IV: Non-gravid reproductive tract of *R. timorensis* showing the uterine body (UB), cervix and vagina. NOTE: The vagina is divided into anterior vagina (av), posterior vagina (pv) and external urethral orifice (euo).

Discussion

The results of the present study have provided a baseline data for the dimensions of the reproductive system of the adult female *R. timorensis*. The knowledge on the anatomy of the female reproductive system is essential for the development of a protocol for artificial insemination as well as pregnancy diagnosis and dealing with infertility problems (Memon, 1996).

One of the most important aspects to be considered when designing an experiment is if adequate replication has been used to provide a reliable outcome. This is very important especially for captive and vulnerable species where cost of replication can quite often be expensive. The parameters of the reproductive tracts measured in *Rusa timorensis* were shown to be adequately

replicated according to the equation described by Morris (1999). It showed that only five *Rusa timorensis* hinds would be required to show a 50% significant difference between *Rusa timorensis* hinds.

The general morphology of the reproductive organs of *R. timorensis* was similar to that of other deer species such as the red brocket deer (*Mazama americana*), pampas deer (*Ozotoceros bezoarticus*) and mouse deer (*Tragulus javanicus*) (Kimura *et al.*, 2004; Ungerfeld *et al.*, 2008; Mayor *et al.*, 2012). However, unlike those of the red brocket deer and mouse deer, the *Rusa* deer uterus did not have an interconual ligament and this implies that the uterine horns are anchored in such a way that sperm deposited into only one uterine horn of the *Rusa* deer will be transported to the other uterine horn (interconual transport).

The ovaries of the *R. timorensis* were significantly smaller than that of the cow and were similar in size and shape to that observed in the sheep and goats and pampas deer (*Ozotoceros bezoarticus*) (Dyce *et al.*, 2002; Konig & Libich, 2007; Ungerfeld *et al.*, 2008; Jaji *et al.*, 2012). Unlike cows, sheep, goats and red brocket deer, the left ovary was slightly larger than the right ovary. This is in contrast to the statement of Rind *et al.* (1999) who observed that the right ovary was on the average slightly larger than the left ovary indicating that the right ovary is more active physiologically than the left ovary.

There were no significant differences in the structure of the oviduct and the ovarian bursa of the *R. timorensis* compared with domestic ruminants (Stalheim *et al.*, 1975; Kimura *et al.*, 1995) and other deer species (Kimura *et al.*, 2004; Ungerfeld *et al.*, 2008; Mayor *et al.*, 2012).

Similarly, as in other deer species (Ungerfeld *et al.*, 2008; Kimura *et al.*, 2004), the uterus of the *R. timorensis* consisted of a small uterine body and two short uterine horns. The length and diameter of the non-gravid uterus recorded in this study were higher than the values recorded by Mayor *et al.* (2012) in the red Brocket deer. The discrepancy may be due to species variation.

References

- Abdulhakeem HE, Mohammad BA, Khaleel J, Zuhair A, Bani I, Mustafa MA, Ashraf NE, & Maen MA (2012). Female reproductive tract anatomy of the endangered Arabian oryx (*Orynx leucorynx*) in Jordan. *Italian Journal of Anatomy and Embryology*, **117**(3): 167 – 174.
- Asher GW (2011). Reproductive cycles of deer. *Animal Reproduction Science*, **124**(3-4): 170 – 175.

The cervix of the *R. timorensis* was characterized by a constricted lumen and six circular folds (cervical rings) which projected into the cervical canal. This was in contrast to the findings of Ungerfeld *et al.* (2008); Dayan *et al.* (2010); and Mayor *et al.* (2012) who observed only four cervical rings in the cervix. This feature should be taken into account when designing effective instrumentation and techniques for transcervical passage of semen during artificial insemination in this species. The length of the catheter should be specifically adapted to the *R. timorensis* cervix anatomy. The 4.4 ± 0.8 cm (cervical length) determines the penetration depth of the catheter. The catheter should have a rigid proximal portion for easy insertion through the cervix and a flexible soft distal tip for non-traumatic and gentle semen transfer. Analysis from the Spearman correlation showed that the number of previous pregnancies had no significant influence on the parameters of the reproductive tracts measured which is an indication that involution of the uterus was not impaired in *Rusa timorensis*.

It could be concluded from this study that the anatomy of female *R. timorensis* reproductive system shares some anatomical characteristics with that of domestic ruminants with few peculiarities such as the absence of interconual ligament in the uterus. The results from this study have provided baseline data on the reproductive anatomy of this vulnerable species, and the knowledge generated can be useful in the development of appropriate reproductive techniques in order to increase its population in captivity and also enable easy detection of its reproductive anomalies, thus strategies to propagate and conserve the species can be established.

Acknowledgement

This research was supported by a grant from Research University Grant Scheme (RUGS), Universiti Putra Malaysia Project 9301400, for which the authors are grateful.

- ANZCCART (2001). Australian and New Zealand Council for the Care of Animals in Research and Teaching. Fact Sheets. www.adelaide.edu.au/ANZCCART/Publications. Retrieved 20-12-2014.
- Clive R (2007). *Domestication*. Greenwood Publishing Group, *Science*. Pp 122 – 126.
- Dahlan I (2009). Characteristics and *Cutability* of Farmed *Rusa* deer (*Cervus timorensis*) carcasses for marketing of venison.

- Asian-Australian Journal of Animal Science* **22** (5): 740 – 746.
- Dayan MO, Besoluk K, Eken E & Ozkadif S (2010). Anatomy of the cervical canal in the Angora goat (*Capra hircus*). Kafkas University. *Veterinary Fak Derg* **16**(5): 847 – 850.
- Dyce M, Sack W & Wensing C (2002). The pelvis and reproductive organs of female ruminants. *Textbook of Veterinary Anatomy, third edition*. Saunders. Pp. 691-712.
- Food and Agriculture Organization (FAO). (1982). *Animal Production and Health Paper 27*. Food and Agriculture Organization, Rome. Pp 3-4.
- International Union for Conservation of Nature (IUCN) (2008). IUCN Red List. www.iucnredlist.org, retrieved 15-04-2012.
- Jaji AZ, Boyi N, Gambo B, Mahre MB, Luka J & Kachamai WA (2012). Pregnancy related biometrical changes in the ovaries and uterus of the red bororo cattle in Maiduguri, Nigeria. *Nigerian Veterinary Journal*, **33**(3): 592 - 599.
- Kimura J, Sasaki M, Endo H & Fukuta K (2004). Anatomical and histological characterization of the female reproductive organs of Mouse deer (Tragulidae). *Placenta*, **25**(6): 705 – 711.
- Kimura J, Yamada H, Tsukise Mori A & Arai K (1995). Production and immunohistochemical characterization of specific antibody to oviductal fluid of miniature Shiba' goat. *Journal of Veterinary Medical Sciences*. **57**(6): 427–431.
- Konig H & Libich H (2007). Female genital organs. *Veterinary Anatomy of Domestic Mammals*. Schattaur, Germany. Pp 432 - 439.
- Mahre MB, Wahid H, Rosnina Y & Jesse FFA (2015). Estrus Response and Pregnancy Rate of *Rusa timorensis* following estrus synchronization with a prostaglandin analogue. *Malaysian Journal of Animal Science* **18** (1): 45 – 53.
- Mahre MB, Wahid H, Rosnina Y, Jesse, FFA, & Azlan CA (2012). Exfoliative vaginal cytology during the oestrous cycle of Rusa deer (*Cervus timorensis*). *Proceedings of the International Conference on One Health and VAM Congress held at Marriott Putrajaya, Malaysia*. Pp 345 – 347.
- Mahre MB, Wahid H, Rosnina Y, Jesse FFA, Azlan CA, Khumran AM, AZ, Jaji (2014). Sperm attributes and morphology on *Rusa timorensis*: Light and scanning electron microscopy. *Animal Reproduction Science* **148** (3-4): 245 – 250.
- Mahre MB, Wahid H, Rosnina Y, Jesse FFA, Azlan CA & Yap KC (2013). Plasma progesterone changes and length of oestrous cycle in Rusa deer (*R. timorensis*). *Animal Reproduction Science* **141**(3-4): 148 - 153.
- Mayor P, López – Plana C & López-Béjar M (2012). Anatomicohistological characteristics of the tubular genital organs of the female Red Brocket deer (*Mazama americana*) in the Peruvian Amazon. *Anatomia, Histologia, Embryologia*, **41**(6): 436-444.
- Memon MA (1996). Diagnosis of pregnancy and infertility by rectal palpation. *Bovine Obstetrics*. Department of Veterinary Clinical Science, Washington State University Pulman. Pp 65 – 68.
- Morris TR (1999). *Experimental Design and Analysis in Animal Science*. CABI Publishing, New York. Pp 1-5.
- Rind M, Brohi A & Bhatti WM (1999). Studies on biometry of ovary during pregnancy in buffaloes. *Proceedings of PASF/PVMA Agro-livestock Conference Lahore, Pakistan*. Pp. 4.
- Semiadi G (2006). *Biologi Rusa Tropis [The Biology of Tropical Deer]*. Puslit Biologi LIPI Press. Pp. 3-4.
- Stalheim OHV, Gallagher JE, & Deyoe BL (1975). Scanning electron microscopy of the bovine, porcine, and caprine uterine tube (oviduct). *American Journal of Veterinary Research*, **36**(6): 1069 – 1075.
- Standing Committee on Agriculture (SCA) (1991). *Farming deer*. Animal Health Committee, CSIRO Australia. Pp 1-3.
- Tapari B (1990). A reappraisal of the development of the Rusa deer resource at Bensbach, Western Province: Success and failures after 25 Years. *Yagl-Ambu*, **15**(4): 32-42.
- Ungerfeld R, González-Pensado S, Bielli A, Villagrán Olazabal D & Pérez W (2008). Reproductive biology of the pampas deer (*Ozotoceros bezoarticus*): A review. *Acta Veterinaria Scandinavica* **50**(6): 1–16.
- Vos, D (1982). *Deer Farming: Guidelines on Practical Aspects*. *FAO Animal Production and Health Paper* No. 27, Rome, Italy. Pp 1-54.