



Evaluation of the knowledge and application of diagnostic imaging modalities among veterinary surgeons in Nigerian veterinary medical schools

CS Ibe^{1*}, AA James² & JO Nzalok³

1. Department of Veterinary Anatomy, Michael Oporokara University of Agriculture Umudike, Nigeria
2. Department of Veterinary Surgery, University of Jos, Nigeria
3. Department of Veterinary Anatomy, Ahmadu Bello University, Zaria, Nigeria

*Correspondence: Tel.: +2348032882105; E-mail: ibe.chikera@mouau.edu.ng

Copyright: © 2019 Ibe *et al.* This is an open-access article published under the terms of the Creative Commons Attribution License which permits unrestricted use, distribution, and reproduction in any medium, provided the original author and source are credited.

Abstract

The awareness, theoretical and practical knowledge of radiography, ultrasonography, magnetic resonance imaging (MRI), computed tomography (CT), nuclear medical imaging (NMI) and thermography were assessed among veterinary surgeons teaching in veterinary schools in Nigeria, using a structured questionnaire. Respondents were grouped into five depending on their years of experience post-graduation. These were Group A (0-5 years), Group B (6-10 years), Group C (11-15 years) Group D (16-20 years) and Group E (> 20 years). The result of the awareness of radiography as a diagnostic imaging modality in veterinary practice was not dependent on the years of research experience. A 100 % of respondents in Group A were aware that ultrasonography is indicated in veterinary practice; while only 96.67 % were aware that radiography is so indicated. There was a gradual decline in the awareness of CT compared to radiography and ultrasonography. There was low awareness of the application of MRI, NMI and thermography in veterinary practice by all respondents irrespective of their years of experience. There was a decline in the degree of theoretical knowledge with advancement in the technique. The variation in the mere observation of the practical demonstration of radiography was related to years of research experience, with the exception of Group D. Group E recorded the highest positive response to practical knowledge of all the diagnostic imaging modalities. There was a remarkable drop in the practical knowledge of CT, MRI, NMI and thermography, compared to radiography and ultrasonography in each of the study groups. Only 1 veterinary school had a CT scanning machine, and none had an MRI unit, a gamma camera or a thermographic camera. Only 4 veterinary schools taught MRI. No veterinary school taught NMI and thermography. Appropriate recommendations were made.

Publication History:
Received: 28-08-2019
Accepted: 25-10-2019

Keywords: CT, MRI, NMI, Radiography, Thermography, Ultrasonography

Introduction

The basic principle of diagnostic imaging is the demonstration of the anatomy of internal body structures and related abnormalities. Diagnostic imaging is also employed in the monitoring of response of patient to treatment regimens (Gantenet *et al.*, 2003). Some of the diagnostic imaging modalities include Radiography, Ultrasonography, Computerized Tomography (CT), Magnetic Resonance Imaging (MRI), Nuclear Medical Imaging (NMI) and Thermography. X-ray was one of the earliest radiations, discovered in 1895 by Wilhelm Roentgen, a German physicist. It utilizes collimated X-ray beam released from the X-ray machine which passes through the patient's body to create an image on the X-ray film. Ultrasonography involves the use of an ultrasound machine which releases ultrasound wave into the internal organs, receives an echo of the sound from the organ and converts same into electrical energy, which is represented on a computer as image of the organ from which the echo was received. Ultrasound, being non-ionizing radiation, is safer than X-ray, thus it is preferred for pregnancy diagnosis. It also produces a real time image.

CT utilizes ionizing radiation to produce thin cross-sectional images of structures such as the head and the brain while MRI utilizes the magnetic property of hydrogen nuclei in the water of the patient's body to generate non-ionizing radiation which produces images of internal organs. Although MRI is more expensive than CT, it is relatively safer than CT because it utilizes non-ionizing radiation. However, it is not recommended for patients with metallic implants because of the reaction between the hydrogen molecules and the metal (Kim *et al.*, 2019). NMI is a more recent diagnostic imaging tool which involves the injection, inhalation or ingestion of tiny radiation particles known as radiotracers or radiopharmaceuticals. The radiotracer has affinity for cancerous cells (Dalm *et al.*, 2017). The radiotracer having reacted with the cancerous cells begins to decay and release gamma rays. A gamma camera is then used in a non-contact fashion with the patient's body to capture the image of the target cell releasing the gamma rays. Thermography, as the name implies, utilizes thermographic or infra-red camera which converts the heat energy generated from an organ to photographic images of the organ.

In Nigeria, reports abound in literature on the veterinary application of X-ray and ultrasonography (Nwaogu *et al.*, 2010; Idris *et al.*, 2016; James *et al.*, 2016; Ubah *et al.*, 2017) in research and clinical diagnosis. Similar studies have also been reported by

researchers in advanced countries (Garosi *et al.*, 2001; De Risio *et al.*, 2009; Labruyere and Schwartz, 2013). However, while there are numerous reports on the application of newer diagnostic imaging modalities such as NMI and thermography in veterinary diagnosis elsewhere (Vainionpaa *et al.*, 2013), similar reports from researchers in Nigeria is lacking in available literature. This denotes a possible limitation in the teaching and application of diagnostic imaging modalities in veterinary medical schools in Nigeria. In their survey, Uwagie-Ero & Awasum (2017) found out that MRI is well established in developed countries across the globe, but remains in its infancy stage in veterinary curriculum and practice in Nigeria. Uwagie-Ero & Awasum (2017) attributed this to the heavy investment cost and maintenance fee as well as lack of professionals. Furthermore, a survey of the level of awareness of diagnostic imaging modalities among health workers in Ahmadu Bello University Zaria has been conducted by Nzalak (2017), but no study has been conducted to access similar awareness among veterinary surgeons in other parts of the country, hence the present research.

The assessment of the awareness and application of diagnostic imaging modalities in Nigerian veterinary medical schools will expose the state of the use of these tools to policy makers and veterinary curriculum developers such as the Nigerian Universities Commission (NUC), the Veterinary Council of Nigeria (VCN). Thus, the results of the present study will be beneficial in planning and decision making by these regulatory bodies. Consequently, the study was aimed at evaluating the awareness, theoretical knowledge, practical knowledge, teaching and application of diagnostic imaging modalities among veterinary surgeons in Nigerian veterinary medical schools.

Materials and Methods

Study area

As at the time of the study (May to July, 2019), veterinary faculties/colleges in eleven (11) Nigerian universities were accredited by the Veterinary Council of Nigeria. These included Ahmadu Bello University Zaria, Federal University of Agriculture Abeokuta, Michael Okpara University of Agriculture Umudike, University of Abuja, University of Agriculture Makurdi, University of Ibadan, University of Ilorin, University of Jos, University of Maiduguri, University of Nigeria Nsukka, and Usman Danfodiyo University Sokoto.

Determination of sample size

The sample size was computed from a target population of 955 academic staff and VTH residents in the accredited veterinary school, obtained from a pilot study. A modification of Cochran's formula for sample size was adopted, and a sample size of 333 was obtained. The structured questionnaire was administered to over 333 respondents. Some questionnaires could not be retrieved, while some were not properly answered and were excluded from the study.

Study design

A close-ended questionnaire was distributed to veterinary surgeons serving as lecturers in the various departments and resident doctors at the Veterinary Teaching Hospitals (VTH). The number of years post DVM degree was adopted as variable. Respondents were grouped into five depending on the years of experience post-graduation. These were Group A (0-5 years), Group B (6-10 years), Group C (11-15) Group D (16-20 years) and Group E (> 20 years).

The design of the questions progressed from mere awareness to theoretical and practical knowledge of the diagnostic imaging modalities. Theoretical knowledge was graded from low to moderate and high knowledge, while practical knowledge ranged from observing any or all of the modalities to actively performing them. Information on the frequency of active performance, ranging from once to twice, thrice and several times was obtained. The respondents were asked if diagnostic imaging was taught as a course or topic in any course at undergraduate or postgraduate level. Information on the practice of the techniques in the study departments were obtained from the respondents. Lastly, the respondents were asked of their view on the introduction of diagnostic imaging in their departments.

Data analysis

The data obtained was subjected to descriptive statistics using GraphPad Prism version 4 for Windows 8. The values were expressed in absolute and relative terms and presented in tables and graphs.

Results

Table 1 is a summary of the number of respondents from veterinary medical schools in Nigeria. A total of 333 respondents were adopted for the evaluation. Table 2 indicated the distribution of the respondents based on years of research experience. Group A, with

36.04 %, recorded the highest number of respondents, while Group D, with 08.41 %, had the least number of respondents.

Evaluation of the awareness of diagnostic imaging modalities

The awareness of diagnostic imaging modalities in veterinary medical schools in Nigeria was represented in Table 3. The result showed that very high percentage of the respondents were aware of radiography as a veterinary diagnostic tool. The range was 96.43 % (Group D) to 98.65 % (Group C). The value increased with increase in years of research experience from Groups A to C. However, Group D recorded the lowest number of respondents. All the 120 respondents in Group A were aware of ultrasonography as a diagnostic imaging modality in veterinary practice, thus recording a value of 100 %. There was a decrease in the values with increase in years of research experience from Groups A to C. Results in Table 3 indicated a reduction in the number of respondents aware of CT as a diagnostic imaging tool in veterinary practice in each group when compared to the values obtained for radiography and ultrasonography in the same group. The only exception is Group C with the same number of respondents (82.43 %) aware of ultrasonography and CT. Similarly, response for the awareness of MRI in veterinary practice was lower than that of CT. The range was 70.27 % (Group C) to 85.71 % (Group D).

The relative number of respondents who were aware of NMI and thermography as diagnostic imaging modalities in veterinary practice was alarmingly lower than was recorded for radiography and ultrasonography. The values indicated a highest value of 71.43 % (Group D) and a lowest value of .83 % (Group A). Similarly, respondents in group D, with a relative number of 60.71 %, recorded the highest number of respondents aware of the existence of thermography as a veterinary diagnostic imaging modality, while respondents in Group A, with a relative number of 31.67 %, recorded the least number of respondents aware of the same imaging modality.

Evaluation of the theoretical knowledge of diagnostic imaging modalities

The distribution of theoretical knowledge of the diagnostic imaging modalities among respondents in Nigerian veterinary medical schools, irrespective of their years of research experience, was represented in Figure 1. The graph showed a steady increase in the number of respondents lacking any theoretical knowledge, with advancement in the imaging

modality, with radiography recording the least and thermography the highest value. Furthermore, the graph clearly indicated that the highest number of respondents indicated that they have high theoretical knowledge of radiography, while the lowest number of respondents indicated that they have high theoretical knowledge of thermography.

Out of the 324 respondents from all groups of years of research experience, who were aware of radiography as a veterinary diagnostic tool, 21 respondents, representing 6.48 %, lack any theoretical knowledge of the modality. Others, measuring 11.42 %, 49.69 % and 32.41 % had low, moderate and high theoretical knowledge of radiography, respectively. Similarly, 23 out of the 314 respondents aware of ultrasonography as a veterinary diagnostic imaging modality, representing 7.33 %, lacked any theoretical knowledge of the modality. Others, measuring 18.47 %, 49.04 % and 25.16 % had low, moderate and high theoretical knowledge of ultrasonography, respectively. For CT, 35 out of 277 respondents aware of the modality, representing 12.64 %, lacked any theoretical knowledge, while 39.71 %, 35.38 % and 12.27 % had low, moderate and high theoretical knowledge, respectively. About 13.75 % of the 269 respondents

aware of MRI in veterinary practice lacked any theoretical knowledge of the technique. Those with low, moderate and high theoretical knowledge represented 41.64 %, 34.94 % and 09.67 %, respectively. Ninety (90) respondents, representing 60.81 % of the 148 respondents that were aware of NMI in veterinary practice, lacked any theoretical knowledge of the modality. Others, measuring 27.70 %, 10.14 % and 01.35 % had low, moderate and high theoretical knowledge, respectively. Lastly, 74.19 % of the 124 respondents aware of thermography, lacked any theoretical knowledge of it, while 21.77 %, 03.23 % and 0.81 % claimed to have low, moderate and high theoretical knowledge of thermography, respectively.

Evaluation of the practical knowledge of diagnostic imaging modalities

Information on mere observation and active involvement in the conduct of the procedure by respondents who were aware of the imaging modalities was analysed based on the years of their research experience. While some of these respondents who have observed the procedures have actively conducted them, others who have observed

Table 1: Distribution of Respondents from Nigerian Veterinary Medical Schools

University	Number of respondents	
	Absolute number	Relative number (%)
Ahmadu Bello University Zaria	53	15.92
Michael Okpara University of Agriculture Umudike	42	12.61
University of Abuja	26	07.81
Federal University of Agriculture Abeokuta	30	09.00
University of Agriculture Makurdi	25	07.51
University of Ibadan	40	12.01
University of Ilorin	28	08.41
University of Maiduguri	10	03.00
University of Nigeria Nsukka	22	06.61
University of Jos	31	09.31
Usmanu Danfodiyo University Sokoto	26	07.81
Total	333	100 %

Table 2: Distribution of Respondents According to their Years of Research Experience Post Graduation

Years of experience	Number of respondents	
	Absolute number	Relative number (%)
Group A [0-5]	120	36.04
Group B [6-10]	82	24.62
Group C [11-15]	74	22.22
Group D [16-20]	28	08.41
Group E [> 20]	29	08.71
Total	333	100 %

them claimed never to have practiced the techniques. The number of respondents from the list of those aware of the procedures, who have observed any of the procedures and the number who have actively conducted any of the procedures was represented in

Table 4. A total of 100 out of the 116 respondents aware of radiography in Group A, representing 86.2 % of the group, claimed to have observed the procedure. The relative value increased with years of research experience up to Group C.

Table 3: Distribution of the Awareness of Diagnostic Imaging Modalities among Veterinary Surgeons in Nigerian Veterinary Medical Schools (n = number of respondents)

Years of Research Experience	Awareness of Diagnostic Imaging Modality	
	Absolute Number	Relative Number (%)
Radiography		
Group A [0-5]; n: 120	116	96.67
Group B [6-10]; n: 82	80	97.56
Group C [11-15]; n: 74	73	98.65
Group D [16-20]; n: 28	27	96.43
Group E [> 20]; n: 29	28	96.55
Total	324	
Ultrasonography		
Group A [0-5]; n: 120	120	100
Group B [6-10]; n: 82	79	96.34
Group C [11-15]; n: 74	61	82.43
Group D [16-20]; n: 28	27	96.43
Group E [> 20]; n: 29	27	93.10
Total	314	
Computed tomography		
Group A [0-5]; n: 120	101	84.17
Group B [6-10]; n: 82	68	82.92
Group C [11-15]; n: 74	61	82.43
Group D [16-20]; n: 28	26	92.86
Group E [> 20]; n: 29	21	72.41
Total	277	
Magnetic Resonance Imaging		
Group A [0-5]; n: 120	102	85.00
Group B [6-10]; n: 82	67	81.71
Group C [11-15]; n: 74	52	70.27
Group D [16-20]; n: 28	24	85.71
Group E [> 20]; n: 29	24	82.76
Total	269	
Nuclear Medical Imaging		
Group A [0-5]; n: 120	43	35.83
Group B [6-10]; n: 82	44	53.66
Group C [11-15]; n: 74	30	40.54
Group D [16-20]; n: 28	20	71.43
Group E [> 20]; n: 29	11	37.93
Total	148	
Thermography		
Group A [0-5]; n: 120	38	31.67
Group B [6-10]; n: 82	29	35.37
Group C [11-15]; n: 74	28	37.84
Group D [16-20]; n: 28	17	60.71
Group E [> 20]; n: 29	12	41.38
Total	124	

Table 4: Distribution of the Practical Knowledge of Diagnostic Imaging Procedure among Veterinary Surgeons in Nigerian Veterinary Medical Schools (n = number of respondents)

Years of Research Experience	Mere observation of the Procedure		Active participation in the procedure		
	Absolute Number	Relative Number (%)	Absolute Number	Relative (%)	Number
Radiography					
Group A [0-5]; n: 116	100	86.2	70	60.34	
Group B [6-10]; n: 80	71	88.75	47	58.75	
Group C [11-15]; n: 73	68	93.15	39	53.42	
Group D [16-20]; n: 27	22	81.48	7	25.93	
Group E [> 20]; n: 28	27	96.43	22	78.57	
Total	288		185		
Ultrasonography					
Group A [0-5]; n: 120	84	70.00	69	57.50	
Group B [6-10]; n: 79	55	69.62	42	53.16	
Group C [11-15]; n: 61	55	90.16	34	55.74	
Group D [16-20]; n: 27	10	37.04	7	25.93	
Group E [> 20]; n: 27	27	100.00	21	77.78	
Total	231		173		
Computed tomography					
Group A [0-5]; n: 101	38	37.62	8	07.92	
Group B [6-10]; n: 68	20	29.41	9	13.23	
Group C [11-15]; n: 61	23	37.70	3	04.92	
Group D [16-20]; n: 26	6	23.08	1	03.85	
Group E [> 20]; n: 21	12	57.14	8	38.10	
Total	99		29		
MRI					
Group A [0-5]; n: 102	26	25.29	4	03.92	
Group B [6-10]; n: 67	18	26.87	8	11.94	
Group C [11-15]; n: 52	25	48.08	5	09.62	
Group D [16-20]; n: 24	5	20.83	1	04.17	
Group E [> 20]; n: 24	10	41.67	6	25.00	
Total	84		26		
Nuclear Medical Imaging					
Group A [0-5]; n: 43	2	04.65	2	04.65	
Group B [6-10]; n: 44	0	00.00	0	00.00	
Group C [11-15]; n: 30	3	10.00	0	00.00	
Group D [16-20]; n: 20	1	05.00	0	00.00	
Group E [> 20]; n: 11	3	27.27	2	18.18	
Total	9		4		
Thermography					
Group A [0-5]; n: 38	4	10.53	2	05.26	
Group B [6-10]; n: 29	2	06.90	1	03.45	
Group C [11-15]; n: 28	2	07.14	0	00.00	
Group D [16-20]; n: 17	0	0.00	0	00.00	
Group E [> 20]; n: 12	5	41.67	3	25.00	
Total	13		6		

The least relative number of respondents was in Group D while the highest was Group E. Similarly, Group E recorded the highest relative number of respondents that have actively conducted

radiography by themselves. All the respondents who were aware of ultrasonography in Group E have observed the procedure.

However, not all of them have actively conducted the procedure; nevertheless, the group recorded the highest relative number of respondents (77.78 %) that have actively conducted ultrasonography, compared to other groups. Conversely, only 37.04 % of respondents in Group D claimed to have observed the procedure. There was a drastic drop in the number of respondents who have observed the conduct of CT and have actively conducted it in each group, compared to the number that had practical knowledge of radiography and ultrasonography in the

same group. This decline was more in NMI and thermography. Only 4.65 % and 18.18 % of respondents in Groups A and E, respectively, have actively conducted NMI procedure. No respondent from Groups B, C and D has actively conducted the procedure. Similarly, no respondent in Groups C and D has actively conducted thermography, while only 1 respondent in Group B, representing 3.45 % of the group had conducted the procedure. The frequency of conducting the diagnostic imaging techniques was represented in Figure 2.

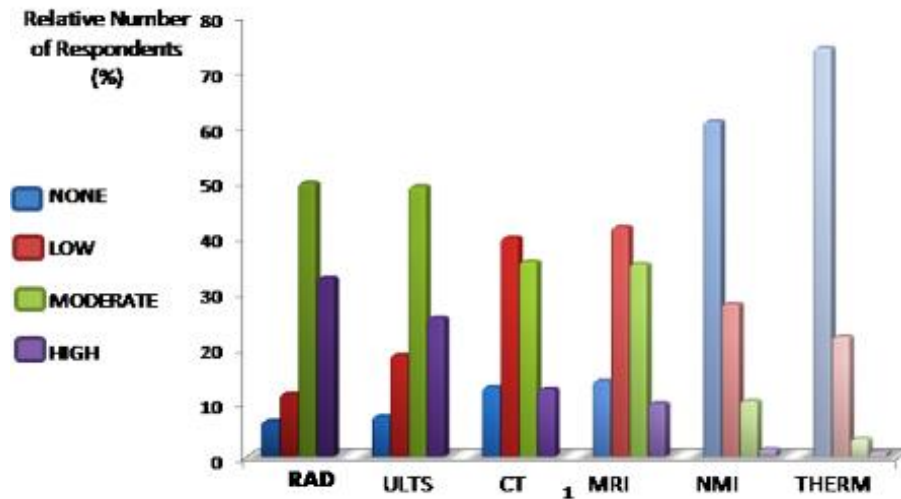


Figure 1: Distribution of the Theoretical Knowledge of Diagnostic Imaging Modalities among Veterinary Surgeons in Nigerian Veterinary Medical Schools
 RAD: Radiography; ULTS: Ultrasonography; CT: Computerised Tomography; MRI: Magnetic Resonance Imaging; THRM: Thermography

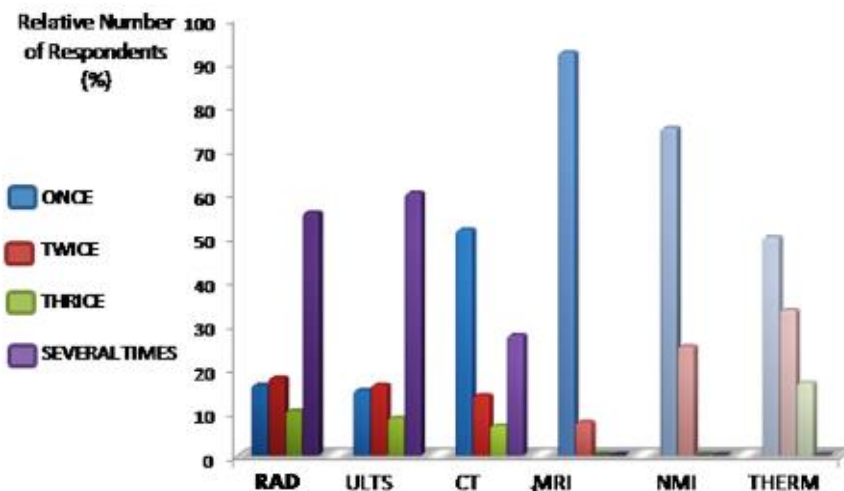


Figure 2: Distribution of the Frequency of conduct of Diagnostic Imaging Modality among Veterinary Surgeons in Nigerian Veterinary Medical Schools
 RAD: Radiography; ULTS: Ultrasonography; CT: Computerised Tomography; MRI: Magnetic Resonance Imaging; THRM: Thermography

A total of 103 out of the 185 respondents that claimed to have conducted X-ray had done so several times. This, representing 55.68 %, was the highest relative number of respondents for the frequency of conduct of radiography. Others included 16.21 %, 17.84 % and 10.27 % for the conduct of radiography once, twice and thrice, respectively. Similarly, the relative number of respondents that have conducted ultrasonography several times (60.12 %) was more than those that have conducted the procedure once (15.03 %), twice (16.18 %) or thrice (8.67 %). A total of 15 out of the 29 respondents (representing 51.72 %) that have conducted CT indicated that they had performed the procedure once. Those that have conducted the procedure twice, thrice or several times were 13.79 %, 6.90 % and 27.59 % respectively. The trend in the frequency of conduct of other diagnostic imaging techniques by the respondents changed from most respondents conducting it several times (as observed for radiography and ultrasonography) to most respondents conducting it once and least number conducting it several times. About 92.31 % have conducted MRI once and 7.69 % twice. No respondent claimed to have conducted the procedure thrice or several times.

Also, 75 % of the respondents claimed to have conducted NMI once while 25 % said they had conducted it twice. No respondent claimed thrice or several times of active demonstration of the procedure. Similarly, 50.00 %, 33.33 % and 16.67 % of respondents who claimed to have actively demonstrated thermography said they conducted the procedure once, twice and thrice, respectively. None of the respondents claimed to have conducted the procedure several times.

Evaluation of teaching and application of diagnostic imaging modalities

Respondents from all the veterinary medical schools stated that radiography, ultrasonography and CT were taught at either undergraduate or postgraduate levels. Respondents from only 4 veterinary medical schools claimed that MRI was taught at either undergraduate or postgraduate levels. Negative response was obtained for the teaching of NMI and thermography in all the veterinary medical schools. Respondents from 10 out of the 11 universities reported the existence of a functional X-ray and ultrasound machines in their veterinary faculty/college. Only one university claimed the availability of a CT scanning machine in their veterinary faculty/college. All respondents affirmed the non-existence of MRI machine, gamma camera

and thermographic camera in their veterinary faculty/college. About 98.20 % of the total number of respondents agreed that X-ray unit is very essential and should be provided for and maintained in all veterinary medical schools. The relative number of respondents who made similar remark for ultrasound, CT, MRI, NMI and thermographic units in Nigerian veterinary medical schools included 97.30 %, 98.50 %, 78.38 %, 72.97 % and 74.17 %.

Discussion

The result of the awareness of radiography as a diagnostic imaging modality in veterinary practice was not dependent on the years of research experience. This is so as respondents with 16-20 years and those with over 20 years of research experience, surprisingly, recorded lower relative number of positive responses compared to respondents with less number of years of research experience. Although the variation in sample size of each group of years of research experience is partly responsible, it was still expected that any veterinary surgeon that had practiced for such duration should be aware that radiography is indicative as a diagnostic imaging modality in veterinary practice. Response to the awareness of radiography and ultrasonography by researchers with not more than 5 years of research experience showed that all the respondents were conversant with the understanding that ultrasonography is indicated in veterinary practice; while a small percentage did not know that radiography is so indicated. This may be linked to the fact that ultrasonography is more applied in veterinary research and diagnosis in Nigeria than radiography. This is so as ultrasonography is cheaper, safer, and produces real time imaging unlike radiography. Also, the availability of portable ultrasound machines and the production of thin sections of images have drawn more research and diagnostic application in veterinary practice with ultrasonography than radiography.

There was a gradual decline in the awareness of CT compared to radiography and ultrasonography, such that the highest relative number of respondents that were aware of CT in veterinary practice was 92.86 % unlike 98.65 % awareness for radiography and 100 % awareness for ultrasonography. Nzalak (2017) reported a similar drop in the awareness of CT among health workers in Ahmadu Bello University Zaria, Nigeria. Although result of this study revealed that CT is taught at either undergraduate or postgraduate level in all the veterinary medical schools, only one veterinary school owns a CT machine. The low level of

awareness of CT as a veterinary diagnostic imaging tool by respondents in whose schools the modality is taught can be due to the fact that the machine is not available for clinical and research use. The availability of the machine will attract more research and clinical practice and case presentations at seminars which will increase the awareness and knowledge of its application in veterinary practice.

Respondents with 16-20 years research experience recorded the highest relative number of awareness of more recent diagnostic imaging modalities (CT, MRI, NMI and thermography). This may be linked to their years of research experience. Also, respondents with not more than 5 years of research experience recorded the lowest relative number of awareness of NMI and thermography. This can also be linked to their years of research experience. However, on a general observation, there was low awareness of the application of MRI, NMI and thermography in veterinary practice by all the respondents irrespective of their years of research experience. The highest relative number of positive response (irrespective of years of research experience) was 85.71 %, 71.43 % and 60.71 % for MRI, NMI and thermography, respectively, unlike 98.65 %, 100 % and 92.86 % for radiography, ultrasonography and CT, respectively. The low awareness of the former diagnostic imaging modalities can be attributed to the lack of teaching of the modalities and the lack of the machines in veterinary medical schools. Only 4 schools teach MRI. No veterinary medical school teaches NMI and thermography. Also, no veterinary medical school owns an MRI machine, a gamma camera or a thermographic camera.

Results that tested the theoretical knowledge of the diagnostic imaging modalities among the respondents indicated a decline in the degree of theoretical knowledge with advancement in the technique. This is measured by the observation of a steady increase in the complete lack of theoretical knowledge from radiography to thermography. It is also explained by the finding that the highest number of respondents had moderate knowledge of radiography and ultrasonography, low knowledge of CT and MRI, and no knowledge of NMI and thermography. This result is not surprising, as the more advanced diagnostic imaging techniques are not taught in Nigerian veterinary schools. Worse still, is the lack of the machines for research and clinical purposes. Elsewhere, Cooley *et al.* (2019) reported that diagnostic imaging services including nuclear medicine, MRI, CT, ultrasonography, digital fluoroscopy and digital radiography are available for

research and diagnostic purposes for large and small animals at the Lois Bates Acheson Veterinary Teaching Hospital of the Carlson College of Veterinary Medicine in Oregon State University. The Pennsylvania Veterinary Teaching Hospital, New Bolton, New York is the first veterinary teaching hospital in the world to use robotic imaging system, according to Dallap-Schaer (2019), the Medical Director of the robotics imaging team (EQUIMAGINE™ TEAM). CT scans obtained using the robotic imaging system offers advantages such as the large animal being awake and standing, with minimal sedation, instead of anaesthesia, scan taken in 30 seconds, producing high quality multi-planar reconstructions and 3D images (Dallap-Schaer, 2019). MRI and nuclear medicine for horses are also available at the teaching hospital (Levine, 2019). In South Africa, diagnostic imaging is offered as a full-time postgraduate programme at the Faculty of Veterinary Sciences, University of Pretoria (Anonymous, 2019).

The variation in the mere observation of the practical demonstration of radiography was related to years of research experience as the relative number of respondents with positive response increased from the least to the highest group based on years of experience. However, this is with the exception of Group D. It is pertinent to mention that with the existence of X-ray unit and ultrasound machines in all the veterinary medical schools, a reasonably percentage of veterinary surgeons who work in those schools have not observed the conduct of these procedures either in the school or elsewhere. The practical demonstration of radiography and ultrasonography is expected to be exposed to veterinary students at undergraduate level. Perhaps the respondents may have passed through their veterinary training when those units were unavailable at their respective schools of training. But with the existence of X-ray unit and ultrasound machine in almost all veterinary schools presently, it is expected that more staff should have at least observed the practical demonstration of radiography and ultrasonography. Result of the present study indicated that respondents with over 20 years of research experience recorded the highest positive response to practical knowledge of all the diagnostic imaging modalities (with the exception of the mere observation of magnetic resonance imaging). This is most probably because of their years of research experience.

The remarkable drop in the practical knowledge of CT, MRI, NMI and thermography, compared to

radiography and ultrasonography by respondents in each of the study groups is worthy of note. This follows the observation that most of these relatively newer techniques are not taught in the veterinary medical schools and the facilities are not even available for research and diagnosis. The very few positive responses were from respondents who had the opportunity to obtain some training abroad. The detrimental effect of the lack of practical knowledge of these imaging modalities by the respondents who teach in the veterinary schools and work at the veterinary teaching hospitals will be felt on the acuity of clinical and research practice involving veterinary radiology. Stadler & O'Brien (2013) reported that the introduction of CT in veterinary practice has greatly improved diagnosis in emergency critical cases or disorders which may be compromised by anaesthesia or sedation as the generation of images is so rapid, thus, important in cases where anaesthesia and sedation are not an option. Levine (2019) listed early and accurate diagnosis of soft tissue injuries associated with lameness in horses as some merits of MRI and the huge importance of nuclear or bone scintigraphy in identifying the cause of large animal lameness. Unfortunately, these, and many more advantages of diagnostic imaging modalities is not presently harnessed in Nigeria due to the lack of expertise and facilities.

Conclusion and Recommendations

The present study has shown that the awareness of radiography as a diagnostic imaging modality in veterinary practice was not dependent on years of research experience. There was low awareness of the application of MRI, NMI and thermography in veterinary practice from all the respondents irrespective of their years of research experience. It was also observed that the variation in the mere observation of the practical demonstration of radiography was related to years of research experience. There was a remarkable drop in the practical knowledge of CT, MRI, NMI and thermography, compared to radiography and ultrasonography. Other findings were that only one veterinary medical school had a CT scanner, none owned an MRI machine, gamma camera or thermographic camera, only 4 veterinary medical schools taught MRI, no veterinary medical school taught NMI and thermography.

From the results obtained in the present study, the following recommendations were proffered

1. University management should encourage staff of the relevant veterinary departments to undertake trainings and re-trainings

abroad on the use of diagnostic imaging modalities in veterinary research and clinics.

2. The Federal Government should set-up modern diagnostic imaging units in veterinary medical schools in Nigeria, and a feasible maintenance policy for such units.
3. The Veterinary Council of Nigeria should include modern diagnostic imaging modalities such as NMI and thermography in the basic minimum accreditation standard (BMAS) requirement for veterinary curriculum in Nigerian veterinary medical schools.
4. In the interim, deans of veterinary medical schools and heads of relevant departments should liaise with Directors of Human Teaching Hospitals, Federal Medical Centers or well-equipped private hospitals within reach of the veterinary schools, for practical demonstration of modern diagnostic imaging modalities for veterinary students.

Acknowledgement

The authors wish to acknowledge the following colleagues who assisted in the distribution and collation of questionnaires from some of the veterinary medical schools. They include Dr. Grace James, Dr. JS Enam, Dr. AA Adeyeye, Dr. Richard OS Okafor, Dr. Adams Mohamed, Dr. Ayobami Raheem and Dr. Nathaniel Wanmi. The authors are also thankful to all the veterinary surgeons who accepted to respond to the questionnaire.

Conflicts of Interest

The authors declare no conflict of interest.

References

- Anonymous (2019). *MMedVe diagnostic imaging (coursework) University of Pretoria*. <https://www.educations.com/study-abroad/university-of-pretoria/mmedve-diagnostic-imaging-coursework-582267>, retrieved 31-07-2019.
- Cooley S, Newsom L & Stieger-Vanegas S (2019). *Veterinary diagnostic imaging at Carloncollege of veterinary medicine, Oregon state university*. <https://vetmed.oregonstate.edu/veterinary-diagnostic-imaging>, retrieved 30-07-2019.
- Dallap-Schaer B (2019). *Robotic imaging at Penn vet., New Bolton center*. <https://www.vet.upenn.edu/veterinary->

- hospitals/NBC-hospital/services, retrieved 31-07-2019.
- Dalm SU, Verzijlbergen JF & De Jong M (2017). Receptor targeted nuclear imaging of breast cancer. *International Journal of Molecular Science*, **18**(2): 260.
- De Rasio L, Adams V, Dennis R & McConnell FJ (2009). Association of clinical and Magnetic Resonance Imaging findings with outcome in dogs with presumptive acute non-compressive nucleus pulposus extrusion: 42 cases (2000-2007). *Journal of American Veterinary Medical Association*, **234**(4): 495-504.
- Ganten M, Radeleff B, Kampschulte A, Daniels MD, Kauffmann GW & Hansmann J (2003). Comparing image quality of flat-panel chest radiography with storage phosphor radiography and film-screen radiography. *American Journal of Radiology*, **181**(1): 171-176.
- Garosi LS, Dennis R, Penderis J, Lamb CR, Targett MP, Cappello R & Delauche J (2001). Results of magnetic resonance imaging in dogs with vestibular disorder: 85 cases (1996-1999). *Journal of American Veterinary Medical Association*, **218**(3): 385-391.
- Idris SA, Audu HA, Lawal M, Ibinaiye PO, Fadason ST, Muazu BN & Echekwu OW (2016). Sonographic diagnosis of pregnancy and study of gastrointestinal changes in rabbit-does. *Nigerian Veterinary Journal*, **37**(3): 133-139.
- James AA, Okaiyeto SO, Allam L, Kwanashie G, Andrew A, Dambrini S & Enam JS (2016). Ultrasonographic diagnosis and clinical management of pyometra in a 6-year old Kano Brown-West African dwarf cross doe. *Veterinary Clinical Practice Bulletin*, **3**(1): 63-68.
- Kim Y, Choi M & Kim J (2019). Are titanium implants actually safe for magnetic resonance imaging examinations? *Archives of Plastic Surgery*, **46**(1): 96-97.
- Labruyere J & Schwartz T (2013). CT and MRI in veterinary patients, an update of recent advances. *In Practice*, **35**(10): 546-563.
- Levine D (2019). *MRI imaging at Penn vet. New Bolton center*.
<https://www.vet.upenn.edu/veterinary-hospitals/NBC-hospital/services/imaging/mri-imaging>, retrieved 31-07-2019.
- Nwaogu IC, Anya KO & Agada P (2010). Estimation of foetal age using ultrasonic measurements of different foetal parameters in red Sokoto goats (*Capra hircus*). *Veterinarski Arhiv*, **80**(2): 225-233.
- Nzalak JO (2017). The level of awareness of veterinary diagnostic imaging modalities among medical and allied professionals in Ahmadu Bello University, Zaria. Fellowship diploma project, Diagnostic Imaging Specialty, Surgery Faculty, Postgraduate College of Veterinary Surgeons, Nigeria. Pp 1-57.
- Stadler K & O'Brien R (2013). Computed tomography of non-anesthetized cats with upper airway obstruction. *Veterinary Radiology and Ultrasound*, **54**(3): 231-236.
- Ubah SA, Rekwot PI, Adewuyi AB, Ababa JA & Mustapha RA (2017). Sonographic evidence of follicle development in a fixed time AI synchronization protocol involving ovariectomy in Bunaji cows. *Journal of Veterinary Medicine and Animal Health*, **9**(7): 143-148.
- Uwagie-Ero EA & Awasum CA (2017). The challenges and limitations of magnetic resonance imaging in veterinary curriculum and clinical practice in Nigeria. *Sokoto Journal of Veterinary Sciences*, **15**(3): 1-9.
- Yusuf AB, Umar IA, Musa UB & Nok AJ (2012). Screening of *Vernonia amygladina* and *Hymenocardia acida* extracts and 1,3-diaminopropane for their antitrypanosomal activities: *in vitro* model. *Journal of Medicine Plants Resource*, **6**(19): 3573-3578.