

## A radiologic study on the urinary bladder following dorsal and ventral cystotomy in mongrel dogs

R.O.C. Kene<sup>1\*</sup>, S.C. Akomas<sup>2</sup>

<sup>1</sup>Department of Veterinary Surgery and Obstetrics, University of Nigeria, Nsukka.

<sup>2</sup>Department of Non-Ruminant Animal Production, College of Animal Science and Animal Health, Michael Opara University of Agriculture, Umudike.

\*Correspondence author

### Abstract

Pneumocystography and positive contrast cystography using solutrast<sup>®</sup> were carried out immediately after surgery and on the second operative day following dorsal and ventral cystotomy in 22 adult mongrel dogs. In all the radiographs, there was no contrast observed in the abdominal cavity and the apex of the bladder had a straight border margin (rather than a curved margin). In both cystotomies, the bladder showed mural defects, which appeared as irregular outline along the bladder suffered. Luminal filling defects were observed in the dorsal cystotomies and in the dorsal cystotomies an obvious indentation was observed on the dorsal surface of the bladder. The absence of contrast in the abdominal cavity suggested that there was no urine leakage from the bladder following the surgery at the second postoperative day. The strait border on the apex was most probably as a result of extra mural pressure produced by the small or large bowel on the bladder. The mural defects observed were due to the incision wounds while the luminal fillings defects observed would most probably be due to the presence of blood clot and or air in the cavity of the bladder at the time the radiographs obtained. The obvious dorsal indentation observed is most probably due to the inflammatory response of the surgical wound.

### Introduction

There has been a reasoning that by virtue of positioning in an upright animal that urine would leak from the ventral rather than the dorsal incision following cystotomy. Gahring (1983) and Wingfield (1979) thought that it was less likely for urine to leak from the dorsal incision. However, Kulkarni and Bhokre (1983), Crowe, (1986) and Desch and Wagner (1986) indicated no urine leakage following either of the incisions. It is also known that the presence of a little tear on the wall of the urinary bladder would result in contrast extravasations in the peritoneal cavity. (Thrall, 1986) and this was the reason for carrying out positive contrast study to appreciate the presence or absence of urine leakage following surgery.

### Materials and Methods

Positive contrast radiograph, of the caudal abdomen were obtained at the second post operative day to determine urine leakage following dorsal and ventral cystotomy in twenty two (22) adult Mongrel dogs. To obtain contrast, the bladder

was filled with solutrast<sup>®</sup> (Byk Gulden Konsten) using a urinary catheter. Filling of the urinary bladder was monitored by abdominal palpation. Radiographs of the caudal abdomen were made of the lateral and ventrodorsal projections immediately after the introduction of contrast and on the second post operative day.

### Results

The radiographs obtained immediately after contrast was introduced in the cavity of the urinary bladder are shown in Figures 1 and 3. Figure 1 was obtained from a ventral cystotomy while Figure 3 was from the dorsal incision. There were mural defects on the ventral aspect of the bladder in Figure 3 and 4. The mural defects appear to irregular outline along the bladder surface.

Figure 2 and 4 were obtained from the ventral and dorsal cystotomies respectively, on the second postoperative day, in order to access whether contrast will the leak out from the urinary bladder incision into the abdomen. In all these radiographs, no contrast was seen to have escaped into the abdominal cavity.

## Discussion

The results of the radiographic studies indicate that there was no leakage of urine in either of the approaches to the urinary bladder. Kulkarni and Bhokre (1998); Crowe (1986); Desch and Wagner (1986) recorded a similar result in their work. The absence of urine leakage following closure of the cystotomy incision could be attributed to the speed of healing of the urinary bladder. Rasmussen (1967) stated that urinary bladder has a high regenerative capacity. Soon after injury, inflammatory response is excited. Fibrin clot quickly plugs that injured area. The fibrin seal on the incision area could possibly account for the absence of leakage of urine. The absence of leakage of urine was confirmed by the fact that radiographic contrast was not seen in the abdominal cavity on the second post operative day.

The presence of a little tear on the bladder would result in contrast extravasations into the peritoneal cavity. The extravasations tend to be slow with small tears (Thrall, 1986). This was the reason for the second exposure on the second post operative day. This time was considered long enough to allow for any leakage of contrast through the surgical incision, assuming there was any tear or leakage from the urinary bladder.

The results of this study appear to contradict the reasoning that there would be a less likelihood of urine leakage following dorsal cystotomy. The assumption that urine would leak out of the ventral incision by virtue of anatomic positioning in an upright animal, has also not been confirmed. One would expect that since fluids obey the law of gravity, that urine ought to leak out from the ventral rather than the dorsal incision but from this study, it is not so. In fact, urine leakage would depend on whether the surgical incisions were adequately sutured. An improperly closed incision will leak regardless of its position so long as the urinary bladders get filled up. Closing the incision with two rows of inverting suture patterns ensures secure closure and provides a watertight seal (Henderson and Pope, 1983) in this study, the incision were closed by Lambert suture pattern. The watertight seal provided by the sutures and the fibrin seal from the inflammatory reaction must have been responsible for the absence of urine leakage observed in this study. It is pertinent to mention that in suturing the incision, the sutures do not pass into the lumen of the bladder as this will most likely result in leakage through the suture materials which are known to have capillary action.

The mural defects observed represents the sites of the incision. They appear as irregularities on the bladder walls. The normal bladder has a transitional epithelium which appears smooth on a contrast cystotogram but mucosal proliferation can occur in response to inflammatory reasons or

chronic irritation. (Park 1978) and this inflammatory reaction explains the irregularities on the bladder mucosa.

The straight border on the vertex in all the radiographs most probably is as a result of extra luminal pressure produced by the small or large bowel. From this the study it is clear that as long as the surgical incision is adequately closed, there would be no likelihood of urine leakage so that wherever there is an indication for cystotomy, the choice of the site of incision should depend on the location of the lesion and the site which most adequately gives surgical exposure to the lesion.

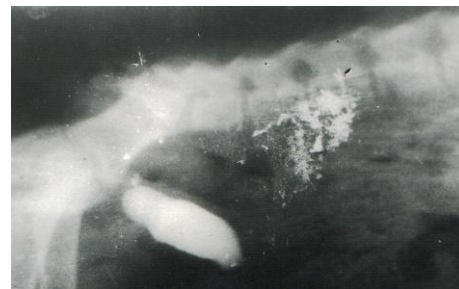

Plate I: Lateral abdominal radiograph after the ventral cystotomy (immediately following the introduction of contrast media) showing irregularities of the ventral wall with no evidence of contrast in the abdominal cavity.

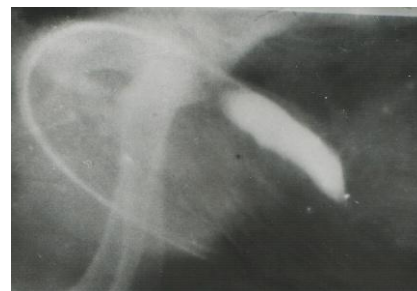


Plate II: Lateral abdominal radiograph after ventral cystotomy, taken on the second postoperative day, showing irregularity of the ventral wall with no evidence of leakage of contrast into the abdominal cavity.



Plate III: Lateral abdominal radiograph after dorsal cystotomy taken immediately after the introduction of contrast showing dorsal irregularities of the dorsal wall with no evidence of contrast in the abdominal cavity. Note the straight border of the vertex and obvious indentation on the dorsal wall.

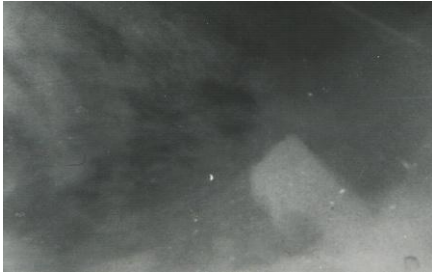


Plate IV: Lateral abdominal radiograph after dorsal cystotomy taken on the second postoperative day, showing dorsal irregularities of the dorsal wall with no evidence of contrast in the abdominal cavity. Note the straight border of the vertex.

## References

- Crowe, D. T. (1986). Ventral versus dorsal cystotomy: an experimental investigation. *Journal of the American Animal Hospital Association*, **22**(3): 382-386.
- Desch, J. P. and Wagner, S. D. (1986). Urinary bladder incisions in dogs. Comparison of ventral and dorsal. *Veterinary Surgery*, **15**(2): 153-155.
- Gahring, D. R. (1983). Surgical Management of canine cystic and urethral calculi. In: (M.J.Bojrab, editor) *Current Techniques in Small Animal Surgery (2nd edition)*. Lea and Febiger, Philadelphia. pp.314-315.
- Kulkarni, D. M. and Bhokre, A. P. (1983). Experimental studies on repair of urinary bladder in buffalo calves II. *Indian Veterinary Journal*, **62**(6): 520-521.