



## Characterization and antifungal susceptibility of *Trichophyton mentagrophytes* isolated from a goat presented with severe dermatophytosis in Zaria, Nigeria

JS Dalis<sup>1\*</sup>, HM Kazeem<sup>1</sup> & KF Chah<sup>2</sup>

- <sup>1.</sup> Department of Veterinary Microbiology, Faculty of Veterinary Medicine, Ahmadu Bello University, Zaria, Nigeria
- <sup>2.</sup> Department of Veterinary Microbiology, Faculty of Veterinary Medicine, University of Nigeria, Nsukka, Nigeria

\*Correspondence: Tel.: +2348069299910; E-mail: dalisjemes280@yahoo.com

### Copyright: © 2023

Dalis et al. This is an open-access article published under the terms of the Creative Commons Attribution License which permits unrestricted use, distribution, and reproduction in any medium, provided the original author and source are credited.

### Publication History:

Received: 07-03-2023

Revised: 10-06-2023

Accepted: 23-06-2023

### Abstract

Dermatophytosis is a contagious skin disease affecting domestic and wild animals with considerable zoonotic significance. The disease is caused by fungi known as dermatophytes in the genera *Trichophyton*, *Microsporum* and *Epidermophyton*. A goat was observed with circumscribed alopecic, highly inflammatory, thickly crusted skin lesions on the head region, especially around the eyes. Skin scraping, including hair pullouts, was aseptically obtained and processed for direct examination, isolation and microscopic identification of etiologic agent and supplemented with urease test. The isolate was tested for its susceptibility to fluconazole, griseofulvin, itraconazole and ketoconazole. Direct examination revealed hyaline, septate hyphae in skin scales and chains of endothrix spores within hair shafts, suggesting *Trichophyton* infection. Colonies on Sabouraud's dextrose agar were white, flat and granular. Microscopic examination of the isolate revealed many oval micro-conidia arranged in grapelike clusters with multi-septate, club-shaped, thin, and smooth-walled macroconidia typical of *Trichophyton mentagrophytes*. The isolate was urease-positive and sensitive to itraconazole and ketoconazole but resistant to fluconazole and griseofulvin. It was concluded that *T. mentagrophytes* was the cause of the severe skin lesions in the goat. The need to perform antifungal susceptibility testing on dermatophytes isolated from clinical specimens for effective management of dermatophytosis was emphasized.

**Keywords:** Dermatophytosis, Goat, *Trichophyton mentagrophytes*, Zaria

### Introduction

Dermatophytosis, also known as tinea or ringworm is one of the most frequently encountered dermatologic problems in veterinary practice (Moretti et al., 2013; Burstein et al., 2020). It is an infection of the superficial layers of the skin, nails, and hair of wild and domesticated animals, and humans.

The causative agents of dermatophytosis are classified into three anamorphic genera: *Microsporum*, *Trichophyton* and *Epidermophyton* (Weitzman and Summerbell, 1995). While the genus *Epidermophyton* consists of only one pathogenic species, *E. floccosum*, and infects only humans, the

genera *Trichophyton* and *Microsporum* contain several pathogenic species and infect both humans and animals (Weitzman and Summerbell, 1995).

The dermatophytes are also grouped into three categories based on their host preference as anthropophilic (human-adapted but rarely transmitted to animals), zoophilic (animal pathogens but do infect humans) and geophilic (soil-associated but may cause both human and animal infections) (Hubka *et al.*, 2018; Burstein *et al.*, 2020).

Dermatophytosis can be transmitted directly between susceptible and infected hosts or indirectly through contact with contaminated fomites (Weitzman and Summerbell, 1995). Specialized pathogens of animals (zoophilic species) and humans (anthropophilic species) are primarily associated with one or few related host species but can potentially cause infection in a broad spectrum of animals. *Trichophyton verrucosum* is the most common species affecting cattle, sheep and goats, while *T. mentagrophytes* and *Microsporum canis* are occasionally isolated (Segal and Elad, 2021).

Dermatophytes are located in the stratum corneum within the keratinocytes. For this reason, it has been suggested that antifungal agents should have the ability to penetrate the stratum corneum cells and remain there to suppress the fungus (Al-Khikani & Ayit, 2020). Most antifungal agents are fungistatic. When these drugs are applied topically, with concentrations achieved in the skin, the growth of dermatophytes is delayed and these are shed with the skin when renewal and healing are achieved (Al-Khikani & Ayit, 2020).

There are three general mechanisms of action for the antifungal agents: inhibition of cell wall formation, cell membrane disruption, and inhibition of cell division (Owens *et al.*, 2010).

Antifungal resistance has been defined as the non-susceptibility of a fungus to an antifungal agent by *in vitro* susceptibility testing, in which the minimum inhibitory concentration (MIC) of the drug exceeds the susceptibility breakpoint for that organism (Kanafani & Perfect, 2008). Microbiological resistance can be primary (intrinsic) or secondary (acquired). Primary resistance is found naturally among certain fungi without prior exposure to the drug and this emphasizes the importance of accurate identification of fungal species from clinical specimens (Kanafani & Perfect, 2008)

The causative agents of dermatophytosis lack the ability to penetrate into organs or deeper tissues of immunocompetent individuals; hence the disease is usually confined to the superficial keratinized layers

of the epidermis, hair and nails (Sardana *et al.*, 2021). In animals, serious consequences are uncommon and infection can be self-limiting with spontaneous regrowth of hairs (Burstein *et al.*, 2020).

This paper reports the isolation and identification of *T. mentagrophytes* from skin lesions of a goat affected by severe highly inflammatory dermatophytosis.

## Case Management

### Case history

A 2-year-old male goat was presented with skin lesions on the ears and face, suggesting dermatophytosis. In this report, four other female goats in the same pen aged between one and five years, including the animal's dam. All the animals in the pen were physically examined but none of the goats showed any visible skin lesions except the male goat in this study. The husbandry practice was semi-intensive whereby the animals were released from the pen in the morning and allowed to roam about and search for feed on their own but usually supplemented with maize bran when they returned to the pen in the evening. After physical examination, a skin scraping including hair pullouts was aseptically collected from the edge of the lesions into a clean envelope for mycological studies at the Department of Veterinary Microbiology Laboratory, Ahmadu Bello University, Zaria, Nigeria.

### Laboratory investigation

A small part of the specimen was placed in two drops of 20% potassium hydroxide (KOH) on a microscope slide and held over a heat source for a few seconds to clear the sample. The heated specimen was covered with a cover glass and examined microscopically using the x10 and x40 objectives of a light microscope for the presence of fungal structures suggestive of dermatophytes (Robert & Pihet, 2008)

The remaining portion of the sample was inoculated onto a plate containing Dermasel agar (Oxoid) and incubated at room temperature for 14 days. The culture was examined twice a week for fungal growth. Colony features such as pigmentation, topography, texture and growth rate were noted.

Microscopic identification of the dermatophyte isolate was performed using the cellophane tape method described by Gohar *et al.* (2019). Briefly, a piece of transparent cellophane tape was looped back on itself with the sticky side out using forceps. The loop was gently pressed to the surface of the fungal growth from the middle out to the edge of the colony to ensure that the various ages of the colony were

sampled (younger growth on the outer edge). The tape, containing fungal structures, was removed from the colony and placed onto a clean, grease-free glass slide containing a drop of lactophenol cotton blue stain. Another drop of lactophenol cotton blue was added directly on top of the cellophane tape and covered with a cover slip. The coverslip was pressed down gently to remove air bubbles and then examined with x10 and x40 objectives of a light microscope. The dermatophyte was identified based on the shape, size and arrangement of macroconidia and microconidia (Frias-De-Leon *et al.*, 2020).

**Urease test:** The Philpot (1967) method was used to determine the urease reaction of the isolate. Briefly, a port of mycelium from the isolated dermatophyte was placed on Christensen's urea agar slant in a universal bottle and incubated at room temperature for 7 days. A change in colour of the medium from orange to pink was considered positive.

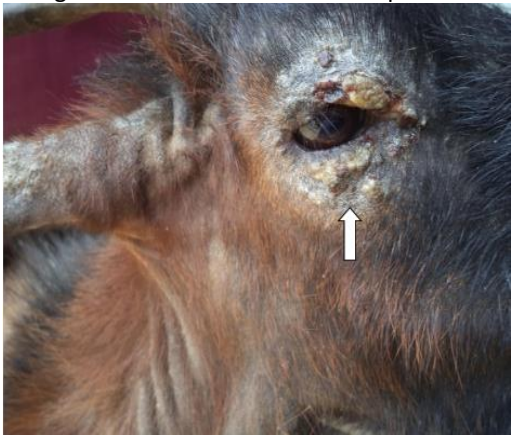**Antifungal disk diffusion susceptibility testing for *T. mentagrophytes* isolate:** The antifungal susceptibility test was conducted as described by Agarwal *et al.* (2015). Mycelium and spores were scraped from a 10-day-old subculture of the isolate and suspended in 3mls of sterile water in a centrifuge tube and the turbidity was adjusted to 0.5 McFarland standards. The suspension was agitated on a vortex mixer to ensure homogeneous solution. A sterile cotton tip swab was dipped into the suspension and excess fluid was removed from the swab by pressing it against the side of the tube above the fluid level. Using the swab, the organism was inoculated onto a plate containing

Sabouraud's dextrose agar (150mm) by streaking back and forth in three directions to cover the entire surface of the medium. The inoculated plate was allowed to dry for 15 minutes. Antifungal sensitivity disks containing itraconazole 8µg/disk, fluconazole 25µg/disk, griseofulvin 25µg/disk, ketoconazole 10µg/disk, were applied to the inoculated medium using a pair of sterile forceps and the disks were pressed down lightly to ensure complete contact with the medium. The plate was incubated at room temperature for 3 days. The zones of inhibition diameters were measured to the nearest whole millimeter for each antifungal agent and interpreted as susceptible, intermediate or resistant.

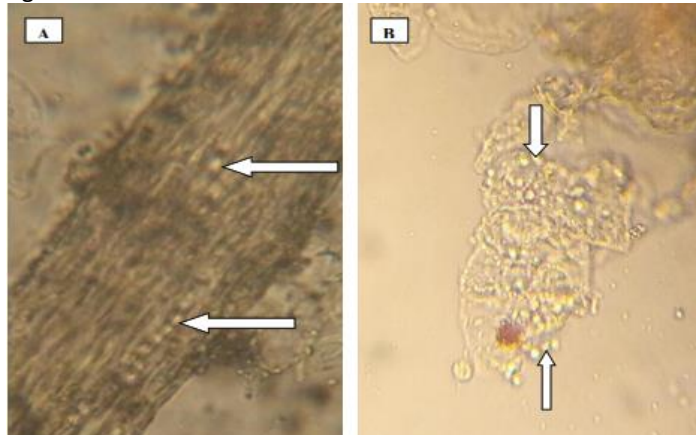
### Result and management

Physical examination of the animal revealed highly inflammatory, discrete, circular, alopecic, thickly crusted periocular lesions (Plate I). Direct examination of the sample showed hyaline septate hyphae in skin scales and endothrix spores in affected hairs (Plate II).

The colony of the isolate on Sabouraud's dextrose agar was flat, white, and granular with a yellow reverse (Plate III). Microscopically, many oval microconidia arranged in grapelike clusters with multi-septate, club-shaped, thin, and smooth-walled macroconidia typical of *T. mentagrophytes* were seen (Plate IV). The isolate hydrolyzed urea indicated by a color change of the medium from yellow to pink (Plate V) and sensitive to ketoconazole (26 mm) and itraconazole (17 mm) but resistant to fluconazole (0mm) and griseofulvin (0mm) (Plate VI).



**Plate I:** A goat severely affected by dermatophytosis caused by *T. mentagrophytes*. Note the circumscribed alopecic, highly inflammatory, thickly crusted peri-ocular lesions (arrow)




**Plate II:** *Trichophyton mentagrophytes* infected hair (A) and skin scales (B) cleared in 10% KOH (x400). Note the chains of hyaline circular spores inside the hair shaft and in skin scales (arrows)

## Discussion

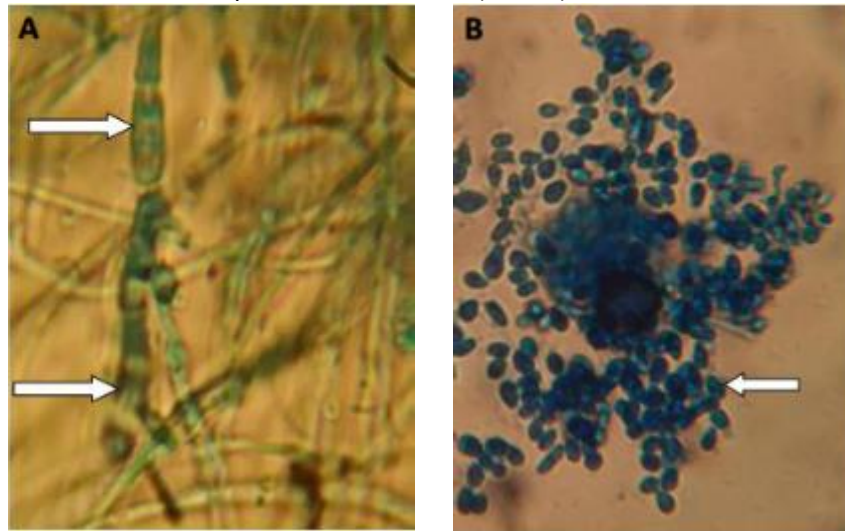
*Trichophyton mentagrophytes* was isolated from a goat affected by severe, highly inflammatory dermatophytosis. The organism was sensitive to ketoconazole and itraconazole but resistant to fluconazole and griseofulvin. The diagnosis was based on clinical signs, direct microscopic examination of the clinical specimen, isolation and microscopic identification of etiologic agent supplemented with a urease test.

The clinical signs in this report were more severe than those reported by Abd-Elmegeed *et al.* (2020), who observed superficial circumscribed areas of hair loss, crusts and scales. This variation may be due to differences in the virulence of the infecting dermatophyte strains and the immune status of the hosts (Hubka *et al.*, 2018). According to Burstein *et al.* (2020), immunocompromised individuals, especially those that suffer from cell-mediated immune deficiency are particularly susceptible to dermatophytosis, showing extensive superficial lesions that are often unresponsive to conventional antifungal therapy. Since the lesions on the animal in this study were unusually highly inflammatory, it was expedient that a detailed microbiological

study be conducted to confirm the tentative diagnosis. For this reason, the results of the different stages of microbiological tests, including direct microscopic examination, colony and microscopic morphology, and urease test which are characteristic of the isolated dermatophyte were documented with clear, unambiguous photographs to prove that the organism isolated from the clinical lesion was indeed *Trichophyton mentagrophytes*. This explains the large number of results generated and presented in this study, although from a single case.



**Plate III:** Surface (A) and reverse (B) colony sides of a 14 day-old culture of *T. mentagrophytes*. Note the white, flat, and granular to fluffy texture of the surface side and the yellowish reverse side (arrows)



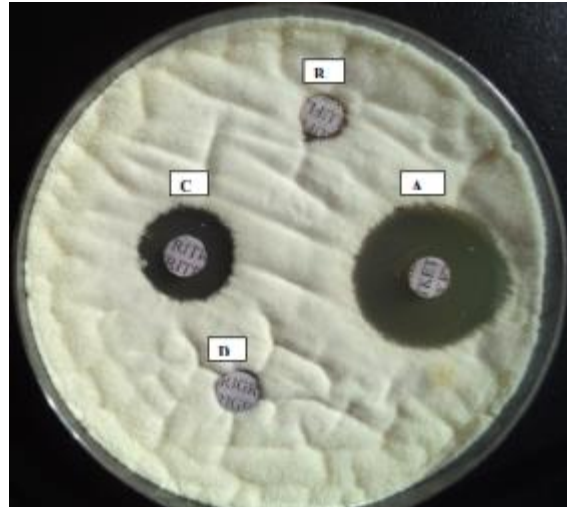
**Plate IV:** Microscopic morphology of *T. mentagrophytes* stained with lactophenol cotton blue (x400). Note the multi-septate, club-shaped, thin, and smooth-walled macro-conidia (A) (arrows) and the many, oval micro-conidia arranged in characteristic grape-like clusters (B) (arrow)

The presence of chains of arthroconidia inside the affected hair shaft was suggestive of *Trichophyton* infection. According to Chermette *et al.* (2008), the dimension and disposition of arthroconidia may vary depending on the infecting dermatophyte species. While *Microsporum* species produce clusters of arthroconidia, spores of the genus *Trichophyton* occur in chains.

Most dermatophyte species are typical in outgrowth and could be readily identified based on their colony appearance in primary culture on Sabouraud's dextrose agar as well as their characteristic



**Plate V:** 5 day-old culture of *T. mentagrophytes* on urease agar. Note the pinkish colour of the test medium compared to the control



**Plate VI:** Agar disk diffusion test for *T. mentagrophytes*. Note the susceptibility to ketokonazole (A) and itraconazole (C) and, resistance to fluconazole (B) and griseofulvin (D)

microscopic morphology such as shape, size, and arrangement of macro- and microconidia (Kane *et al.*, 1997). The colony morphology of *T. mentagrophytes* in this study was consistent with the report of Frias-De-Leon *et al.* (2020), who described the colony of *T. mentagrophytes* as white, flat and powdery. The colony appearance of primary cultures on SDA as well as host preference has been cited as useful criteria for differentiating between *T. mentagrophytes* and *T. interdigitale*. Whereas *T. mentagrophytes* (zoophilic) produces powdery or granular colonies, *T. interdigitale* (anthropophilic) forms cottony colonies (Kane *et al.*, 1997). In contrast, colonies of *T. verrucosum*, are glabrous, raised at the center, and have flat periphery with some submerged growth (Kane *et al.*, 1997).

In this study, the presence of multiseptate, thin, smooth-walled macroconidia and many oval microconidia arranged in loose grapelike clusters typical of *T. mentagrophytes* is consistent with the reports of Nenoff *et al.* (2007), Zhang *et al.* (2019) and Frias-De-Leon *et al.* (2020) who reported that the macroconidia of *T. mentagrophytes* originate laterally in the hyphae or in short pedicles of thin or thick walls and are club-shaped or fusiform, with a size that varies from 4–8 to 8–50  $\mu\text{m}$ . There appears to be a consensus among researchers that the most consistent feature of *T. mentagrophytes* is the production of abundant globose microconidia arranged in groups (Zhang *et al.*, 2019; Frias-De-Leon *et al.*, 2020; Dalis *et al.*, 2020).

Although *T. mentagrophytes* and *T. interdigitale* present microscopic features that are not distinguishable from each other, they can however, be differentiated based on their macroscopic morphology on SDA (Dhib *et al.*, 2017). Frias-De-Leon (2020) was able to identify 46 isolates of *T. mentagrophytes* and nine isolates of *T. interdigitale* which were genotypically identical on the basis of their colony morphology on SDA. Similarly, Dhib *et al.* (2017) found that the amplification reactions of a fragment of the ITS1-5.8S-ITS2 regions of the ribosomal RNA (rRNA) gene did not provide a powerful alternative for the identification of *T. interdigitale* and could only be identified as *T. mentagrophytes* complex at the molecular level. Hence, they concluded that, since the morphological analysis of colonies on SDA led to their preliminary identification, it should not be ruled out for the identification of species in this complex.

*Trichophyton verrucosum* is easily differentiated from *T. mentagrophytes* by its formation of large clavate to pyriform microconidia which are borne singly and laterally along the hyphae. Macroconidia are rarely produced, but when present, they are sinuous (having many curves) with a characteristic tail or string bean shape (Kane *et al.*, 1997).

The hydrolysis of urea by the *T. mentagrophytes* isolated in this study confirms the report of Philpot (1967), who studied 70 isolates of *T. mentagrophytes*, 104 isolates of *T. rubrum* and eight isolates of *T. erinacei* for their ability to split urea. He found that

92.8% of *T. mentagrophytes* were positive within seven days but no isolates of *T. rubrum* and *T. erinacei* split urea, and comparing the urease and hair perforation tests, he concluded that the urease test offers a rapid and reliable method of separating these two species.

Dermatophytes can vary in their susceptibility pattern to antifungal agents; hence, relative or absolute resistance may occur (Agarwal *et al.*, 2015). The resistance of *T. mentagrophytes* to fluconazole and griseofulvin in this study is similar to the report of Robertson *et al.* (1982) who demonstrated the efficacy of ketoconazole in the treatment of patients who failed to respond to griseofulvin therapy and, that of Fattah *et al.* (2020) who reported a multidrug-resistant *T. mentagrophytes* genotype VIII in an Iranian family with generalized dermatophytosis. This genotype was found to exhibit resistance to terbinafine, itraconazole, and fluconazole. Although it has been observed that dermatophyte species are closely related to each other phylogenetically, and drugs that are effective against one species are also effective against others (Gupta *et al.*, 1999), however, the findings in this study suggest the need to perform antifungal susceptibility testing on dermatophytes isolated from clinical specimens for proper management of dermatophytosis.

#### Funding

No funding was received.

#### Conflict of Interest

The authors declare that there is no conflict of interest.

#### References

Abd-Elmegeed MM, El-Mekkawi MF, Diasty EM & Fawzi EM (2020). Dermatophytosis among ruminants in Egypt: The infection rate, identification and comparison between microscopic, cultural and molecular methods. *Zagazig Veterinary Journal*, **48**(2): 116-127.

Agarwal RK Gupta S, Mittal G, Khan F, Roy S & Agarwal A (2015). Antifungal susceptibility testing of dermatophytes by agar based disk diffusion method. *International Journal of Current Microbiology and Applied Sciences*, **4**(3): 430-436.

Al-Khikani FHO & Ayit AS (2020). Major challenges in dermatophytosis treatment: Current options and future visions. *Egyptian Journal of Dermatology and Venereology*, **41**(1): 1-9.

Burstein VL, Beccacece I, Guasconi L, Mena CJ, Cervi L & Chiapello LS (2020). Skin immunity to dermatophytes: from experimental infection models to human disease. *Frontiers in Immunology*, doi.10.3389/fimmu.2020.605644.

Chermette R, Ferreiro L & Guillot J (2008). Dermatophytoses in Animals. *Mycopathologia*, doi.10.1007/s11046-008-9102-7

Dalis JS, Kazeem HM, Kwaga JKP & Kwanashie CN (2020). Dermatophytosis caused by *Trichophyton mentagrophytes* in an 8-month-old Bunaji cross breed calf in Jos, Plateau State, Nigeria. *Nigerian Veterinary Journal*, **40**(4): 1-9.

Dhib I, Khammari I, Yaacoub A, Hadj SF, Ben SM, Zemni R & Fathallah A (2017). Relationship between phenotypic and genotypic characteristics of *Trichophyton mentagrophytes* strains isolated from patients with dermatophytosis. *Mycopathologia*, **182**(5-6): 487-493.

Fattah A, Shivani F, Ayatollah A, Rezaei-Matehkolaei A, Badali H, Lotfali E, Ghasemi R, Pourpak Z & Firooz A (2020). Multidrug-resistant *Trichophyton mentagrophytes* genotype VIII in an Iranian family with generalized dermatophytosis: report of four cases and review of literature. *International Journal of Dermatology*, **60** (6): 686-692.

Frias-De-Leon MG, Herrera EM, Atoche-Dieguez CE, Gonzalez-Cespon JL, Uribe B, Arenas R & Rodriguez-Cerderra C (2020). Molecular identification of isolates of the *Trichophyton mentagrophytes* complex. *International Journal of Medical Sciences*, **17**(1): 45-52.

Gohar NM, El-Bata HM, Elawady B. A & Samir N (2019). Phenotypic methods versus PCR-RFLP for the identification of dermatophyte species isolated from patients with dermatophytosis in Egypt. *African Journal of Clinical and Experimental Microbiology*, **20**(2): 117 – 126.

Gupta AK, Hofstader SL, Adam P & Summerbell RC (1999). *Tinea capitis*: an overview with emphasis on management. *Pediatric Dermatology*, **16**(3): 171-189.

Hubka V, Peano A, Cmokova A & Guillot J (2018). Common and Emerging Dermatophytoses in Animals: Well-known and New Threats. In: *Emerging and Epizootic Fungal Infections in Animals* (S Seyedmousavi, GS de Hoog, J

- Guillot, PE Verweiji, editors). Springer International, Berlin/Heidelberg, Germany, Pp 31-79.
- Kanafani ZA & Perfect JR (2008). Resistance to antifungal agents: mechanisms and clinical impact. *Clinical Infectious Diseases*, **46**(1): 120-128.
- Kane J, Summerbell RC, Sigler L & Kraiden SLG (1997). *Laboratory Handbook of Dermatophytes*. Star Publishers, Belmont CA, USA. Pp 157-158.
- Moretti A, Agnetti F, Manciatnti, F, Nardoni S, Righi C, Moretta I, Morganti G & Papini M (2013). Dermatophytosis in animals: Epidemiological, clinical and zoonotic aspects. *Giornale Italiano di Dermatologia e Venereologia*, **148**(6): 563-572.
- Nenoff P, Herrmann J & Graser Y (2007). *Trichophyton mentagrophytessive interdigitale? A dermatophyte in the course of time*. *Journal der Deutschen Dermatologischen Gesellschaft*, **5**(3): 198–202.
- Owens JN, Skelley JW & Kyle JA (2010). The fungus among us: an antifungal review. *US Pharmacist*, **35**(8): 44-56.
- Philpot C (1967). The differentiation of *Trichophyton mentagrophytes* from *T. rubrum* by a simple urease test. *Sabouraudia*, **5**(3): 189-193.
- Robertson MH, Ric P, Parker F & Hanifin JM (1982). Ketoconazole in griseofulvin resistant dermatophytosis. *Journal of American Academy of Dermatology*, **6**(2): 224-229.
- Robert R & Pihet M (2008). Conventional methods for the diagnosis of dermatophytosis. *Mycopathologia*, **166** (5-6): 295-306.
- Sardana K, Gupta A & Mathachan SR (2021). Immunopathogenesis of dermatophytoses and factors leading to recalcitrant infections. *Indian Dermatology Online Journal*, **12**(3): 389-399.
- Segal E & Elad D (2021). Human and zoonotic dermatophytoses: epidemiological aspect. *Frontiers in Microbiology*, doi.10.3389/fmicb.2021.713532.
- Weitzman I & Summerbell RC (1995). The dermatophytes. *Clinical Microbiology Reviews*, **8**(2): 240–259.
- Zhang M, Jiang L, Li F, Xu Y, Lv S & Wang B (2019). Simultaneous dermatophytosis and keratomycosis caused by *Trichophyton interdigitale* infection: a case report and literature review. *BMC Infectious Diseases*, doi.10.1186/s12879-019-4612-0.