



Comparative study on the sensitivity of bacteriology and immunohistochemical technique in the diagnosis of natural salmonellosis in chickens

FM Mshelbwala^{1*}, SNA Saidu², CN Kwanashie², AKF Kadiri², EO Anise¹, EL Nyillah²
& NDG Ibrahim²

¹ College of Veterinary Medicine, Federal University of Agriculture, Abeokuta

² Faculty of Veterinary Medicine, Ahmadu Bello University, Zaria Nigeria

*Correspondence: Tel.: +2348025879578; E-mail: mshelbwalafakilahyel@yahoo.com

Copyright: © 2018 Mshelbwala *et al.* This is an open-access article published under the terms of the Creative Commons Attribution License which permits unrestricted use, distribution, and reproduction in any medium, provided the original author and source are credited.

Publication History:
Received: 06-04-2017
Accepted: 14-09-2017

Abstract

Bacteriological and immunohistochemical diagnoses of natural salmonellosis in chickens were carried out on 36 cases, in order to compare the sensitivities of the two techniques. Samples of the lungs, heart, liver, spleen, kidneys, proventriculus, intestine and caecum were collected at postmortem for bacterial isolation and separately fixed in 10% formalin for immunohistochemistry. The frequencies of *Salmonella* isolation by bacteriology and antigen detection by immunohistochemical technique were determined from the tissue samples and overall percentages between the two were compared. Out of 36 cases of natural salmonellosis, 53 *Salmonella* isolates were obtained from different organs in 31 (86.1%) cases; 48 isolates from 28 (77.8%) cases tested biochemically positive; PCR confirmed 41 isolates from 25 (89.3%) cases. Immunohistochemical test was positive in all the 36 (100%) cases. In the present study, immunohistochemical technique was more sensitive than isolation and identification and can be used as an adjunct to bacteriology in the diagnosis of avian salmonellosis.

Keywords: Salmonellosis, Diagnosis, Bacteriology, Immunohistochemistry, Postmortem, Chicken

Introduction

Avian salmonellosis in Nigeria is one of the most devastating bacterial diseases in the poultry industry (Muhammed, 2008) resulting in retarded growth, decreased meat production, increased cost of treatment and mortality (Kabir, 2010). Intensive poultry rearing is confronted with extremely complicated disease complexes in which salmonellosis occupy an important place (Majid *et al.*, 2010).

Salmonella Gallinarum was isolated in three separate outbreaks on farms in Abeokuta, but the gross and histopathological lesions associated with

the disease have not been described. Furthermore, outbreaks of unconfirmed aetiologic agents were reported in other parts of Ogun State and the Southwestern Nigeria within the same period (Agbaje *et al.*, 2010).

While various researches on salmonellosis have been done on the prevalence, isolation and identification, antibiotic resistance and susceptibility in different parts of the Nigeria (Okwori *et al.*, 2007; Mbuko *et al.*, 2009; Agbaje *et al.*, 2010; Ajayi & Egbebi, 2011; Fasure *et al.*, 2012), the most sensitive, fast and

reliable method of diagnosis of avian salmonellosis is still a challenge in developing countries.

The clinical evaluation of the disease is difficult and is even impossible to diagnosis by symptoms alone. The disease results in a morphopathological picture with few macroscopic characteristics, despite the importance of avian salmonellosis (Henderson *et al.*, 1999; Kabir, 2010). Gross and histopathological lesions described internationally may present differently in some cases (Shivaprasad & Barrow, 2008).

Diagnosis of avian salmonellosis is done based on clinical signs, serologic test, gross and histopathological lesions (Shivaprasad, 1997; Shivaprasad & Barrow, 2008), but confirmation is done by isolation, identification and serotyping of *Salmonella* strains (Kabir, 2010; Majid *et al.*, 2010). There is a fast and reliable diagnostic test based on real time PCR system that is used to specifically detect *S. Enteritidis* and *S. Typhimurium* for monitoring purposes in the poultry food chain (Szmolka *et al.*, 2006).

Immunohistochemistry (IHC) is a combination of immunologic and chemical reactions visualized with a photonic microscopy that is very sensitive and highly specific (100%) diagnostic tool for the diagnosis of prion diseases (Myers, 2004; Rasmos-vara *et al.*, 2008)). It has been used for the diagnosis of infections caused by *Salmonella* species in domestic animals (Beyaz & Kutsal, 2003). In some cases, IHC is considered the gold standard technique to which others are compared especially in prion diseases (Myers, 2004; Rasmos-vara *et al.*, 2008). In comparison with other diagnostic tests, IHC allows localization of an antigen within lesions, thereby dramatically increasing diagnostic accuracy and understanding of pathogenesis (Beyaz & Kutsal, 2003; Rasmos-vara *et al.*, 2008) and has advantage over bacteriology (isolation and identification) because it can detect the antigen in the tissue even as the organism is dead, unlike bacteriology that requires the organism to be alive (Beyaz *et al.*, 2010). Despite the high sensitivity and specificity of IHC, the technique has not been routinely used in the diagnosis of avian salmonellosis (Rasmos-vara *et al.*, 2008; Beyaz *et al.*, 2010). The present study determined the more sensitive method between bacteriology and immunohistochemical technique, in the diagnosis of avian salmonellosis in chickens.

Materials and Methods

Postmortem examination

Two hundred and thirty chickens comprising of those aged 1 to 3 weeks (13%); 4 to 8 (31%); as well as 9 and above (56%) that died from 36 outbreaks of salmonellosis in commercial poultry farms in the study area (Lagos, Ogun and Oyo states of Nigeria); and submitted for postmortem examination were used for the study. The breeds of the chickens were Isa brown (47%); Nera black (36%), Local chickens (7%), Lona black (4%), Boron black (3%), Dominant black (3%). The most predominant chicken-type was layers (57%), followed by broilers (24%), cockerels (16%) and breeders (3%). The carcasses of the chickens were submitted within 18 hours after death and were confirmed to be fresh before postmortem examinations were carried out. Clinical histories associated with disease were recorded. The carcasses were examined for gross lesions in different outbreaks at different times over a period of one year (January to December, 2013). 118 numbers of postmortem cases were recorded during the study period, out of which suspected cases of salmonellosis were sorted out from the postmortem records.

Sample collection from natural cases of salmonellosis

Two sets of samples were collected, one for bacterial isolation and identification and the other for immunohistochemistry. Tissue samples of the lung, heart, liver, spleen, kidney, proventriculus, small intestine and caecum from each of the 36 suspected cases of avian salmonellosis (288 samples) were aseptically collected and placed into sterile sample bottles for bacterial isolation and identification in the Department of Veterinary Microbiology, College of Veterinary Medicine, Federal University of Agriculture, Abeokuta (FUNAAB). The bile was also collected for bacterial isolation and identification. Samples from the same organs were also collected and fixed immediately in 10% neutral buffered formalin for at least 48 hours for immunohistochemistry in the Department of Veterinary Pathology, FUNAAB.

Bacterial culture

Swabs from aseptically sectioned tissue samples of the organs collected at postmortem were separately inoculated into nutrient broth and buffered peptone water for pre-enrichment and incubated at 37°C for 24 hours. Samples from the pre-enrichment media were inoculated into 50ml of Rappaport-Vassiliades broth (Oxoid, Basingstoke, UK) following the pre-enrichment for selective enrichment and incubated at 37°C for 24 hours as described by AAAP (1998)

and onto Tetrathionate glucose broth (Oxoid, Basingstoke, UK). Using a sterile wire loop, a loopful of each incubated broth culture was inoculated onto Xylose Lysine Desoxycholate Agar (XLD) (Oxoid, Basingstoke, UK) and incubated at 37°C for 24 hours. The plates were examined for typical colonies of *Salmonella* as described by AAAP (1998). The colonies from these plates were further subcultured on XLD (Oxoid Basingstoke, UK) and incubated at 37°C for 24 hours. The plates from the subculture were observed for typical colonies of *Salmonella* as described by AAAP (1998). Suspected *Salmonella* colonies were inoculated onto MacConky agar for purification. The suspected *Salmonella* isolates were later inoculated onto nutrient slant and kept in a fridge at 4°C for biochemical tests.

Polymerase chain reaction procedure

Suspected *Salmonella* samples isolated in FUNAAB Microbiology Laboratory were put on nutrient slant and sent to the National Veterinary Research Institute (NVRI), Vom, Plateau State. The isolates were confirmed by conventional polymerase chain Reaction (PCR).

A set of primer pair 139-141 specific for the *invA* gene from *Salmonella* species was used (Galan *et al.*, 1992). The primer sequences were as follows: *invA*-F 5-3¹GTGAAATTATCGCCACGTTCCGGCA and *invA*-R 5-3¹TCATCGACCGTCAAAGGAACC with amplification product of 284bp (Szmolka *et al.*, 2006; Cha *et al.*, 2008; El Tigani *et al.*, 2013).

Immunohistochemical techniques

Procedure for Immunohistochemistry: Standard immunohistochemistry method; Avidin Biotin Streptavidin Peroxidase Complex (ABC) method was applied as described by various workers (Shi *et al.*, 1999; Myers 2004; Rasmus-vara, 2005). The tissue sections from the formalin fixed paraffin embedded tissues were cut into two part each and mounted on poly-l-lysine coated glass slides separately; one part served as the test sample while the other as control. They were then incubated in an oven at 60°C for 1 hr. Tissue sections were then deparaffinized in xylene and rehydrated with graded alcohol and rinsed with distilled water. Antigens were retrieved by placing the tissue sections on the glass slides in a microwave-resistant plastic staining jar containing antigen retrieval solution and it was ensured that they were carefully covered with the solution, and placed in a microwave oven, which was operated for 5 mins on high power (» 700 watts) and allowed to cool before opening. Endogenous peroxidase was

blocked with 1% H₂O₂ in methanol for 15 min and 10% normal goat serum (KPL, Product Code 710027, USA) was applied on sections to block non-specific binding of immunoglobulins. *Salmonella* polyclonal antibody raised in rabbits (Novus Biologicals, NB 100-64498, USA) at a dilution of 1:800 in phosphate buffered saline (PBS) (Ph 7.4) (Sigma Aldrich, Catalog number P4417, USA) was applied on tissue sections and were incubated in a humidified chamber and placed in a refrigerator for 24 hrs.

Biotinylated goat anti-rabbit secondary antibody (KPL, Product Code 710030, USA) and Streptavidin peroxidase enzyme (KPL, Product Code 710038) were applied on sections for 10 mins each. 3-amino-9-ethylbenzidine (AMRESCO, Product Code E733, USA) chromogen was applied on sections for colour development. Sections were rinsed with distilled water and counterstained with Gill's Haematoxylin for 2 mins, and mounted with aqueous mounting solution. The same procedure, except application of primary antibody, was carried out on tissues prepared for positive control.

Comparison of the sensitivity of bacteriology and immunohistochemical technique: Comparison to determine the sensitivity of bacteriology and immunohistochemical technique was carried out as follows:

The numbers of *Salmonella* positive samples were sorted out from the total number of samples submitted for bacterial culture and identification and the percentage of *Salmonella* isolation and identification was calculated. Similarly, the numbers of *Salmonella* antigen positive samples were sorted out from the total number of tissues tested by immunohistochemical technique and the percentage of antigen detection was calculated. The overall percentages between bacterial isolation and identification and immunohistochemical technique were compared (Table 1).

Results

Clinical signs

The clinical signs observed in the present study were weakness, anorexia, somnolence, greenish to yellowish diarrhea and mortality of 40 to 60%.

Gross lesions

The carcasses were fresh and majority was fleshed (70%). The vents were soiled with watery faecal materials (80%). There were severe pulmonary congestion and oedema in 100% of the cases. The coronary blood vessels were congested and there

Table 1: Rate of diagnosis of salmonellosis cases in chickens submitted from Lagos, Ogun and Oyo States, Nigeria by different methods, in 2013

Diagnostic method	Number of suspected cases of salmonellosis tested	Number of positive cases	Percentage of detection (%)
Clinical signs	43	31	72.1
Postmortem examination	36	31	86.1
Culture and isolation	36	31	86.1
Biochemical test	31	28	90.3
Polymerase Chain Reaction	28	25	89.2
Immunohistochemistry	36	36	100

were pale foci of necrosis on the myocardium with nodular enlargement of the heart (40%). The liver, spleen and kidneys were markedly enlarged and had sub-capsular multifocal necrosis (90%). The proventriculus contained large amounts of mucus and the mucous membranes were hyperemic (100%). The intestines were distended with watery diarrhoeic faeces and moderate amount of mucus (catarrhal enteritis) and the mucous membranes were hyperemic (100%). The caeca contained caecal core and the caecal tonsils were necrotic (80%).

Bacteria culture

The *Salmonella* isolates appeared smooth, pinkish to red with black centres on XLD agar, smooth and pale/colourless on MacConkey and smooth, translucent and slightly raised on Nutrient Agar. The *Salmonella* isolates were gram negative, short, rod shaped, and motile organisms.

Biochemical analyses

Biochemical analyses showed that the bacteria isolates were catalase positive, oxidase negative; produce an alkaline slant (red) over an acid butt (yellow) in triple sugar iron (TSI). They were citrate positive, indole negative, methyl red positive, urea hydrolysis (urease) negative.

Polymerase chain reaction

The PCR amplicons on 1.5 agarose gel for the identification of *Salmonella species* are presented in Figure 1. The PCR result showed that positive samples and the positive control; for *S. Enteritidis* corresponds to 284 bp on the ladder of the

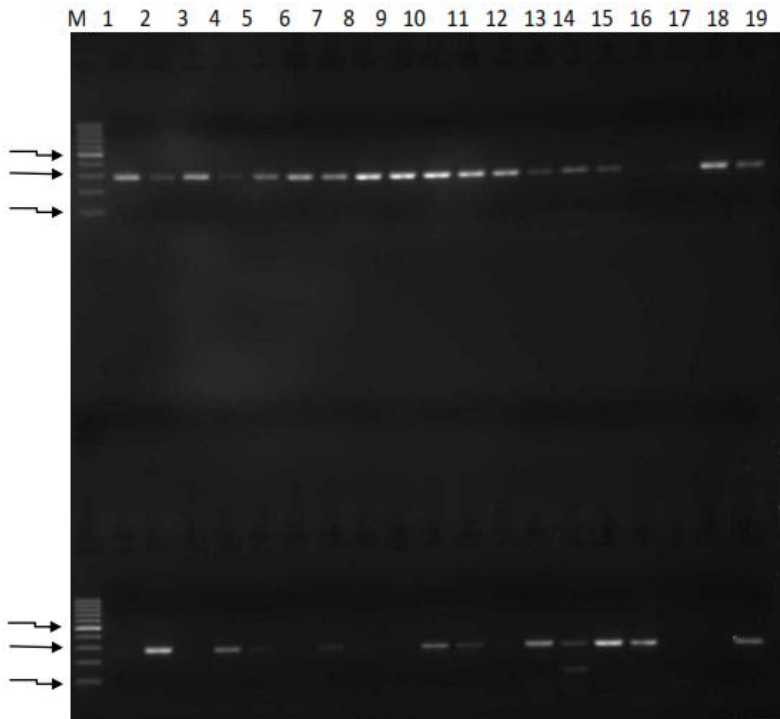


Figure 1: PCR amplicons on 1.5 % gel for *Salmonella species* from Lagos, Ogun and Oyo States. Lane M: Molecular markers of 100 bp ladder each; Lane 1 to 19 (first row): Samples; Lane 1 to 17 (second row): samples; Lane 18 (second row): negative control, *Proteus vulgaris*; Lane 19 (second row): positive control, *Salmonella* Enteritidis. Samples of *Salmonella* species and the positive control, *Salmonella* Enteritidis correspond to the 284 bp

molecular marker, which is the base pair unique for all *Salmonella* species.

Immunoreactions

Immunoreactions were observed in necrotic debris and cytoplasm of epithelial cells, hepatocytes, myofibers, macrophages, lymphocytes and heterophils in all the visceral organs tested (100) (Plates Ia-VIIIa). There were no immunoreactions observed in control tissue sections not incubated with *Salmonella* antibody (Plates Ib-VIIIb).

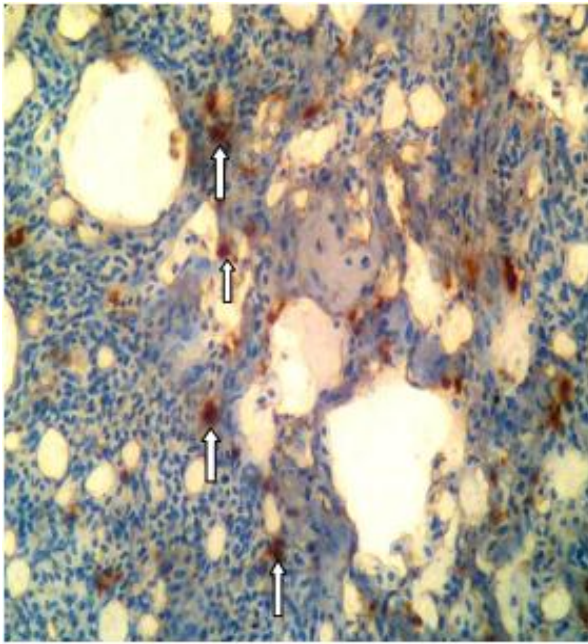


Plate Ia: Section of the lung of an adult Isa brown chicken that died from a natural case of avian salmonellosis, showing immunoreactions to *Salmonella* antigen in macrophages (arrows) (x400; immunohistochemical reaction)

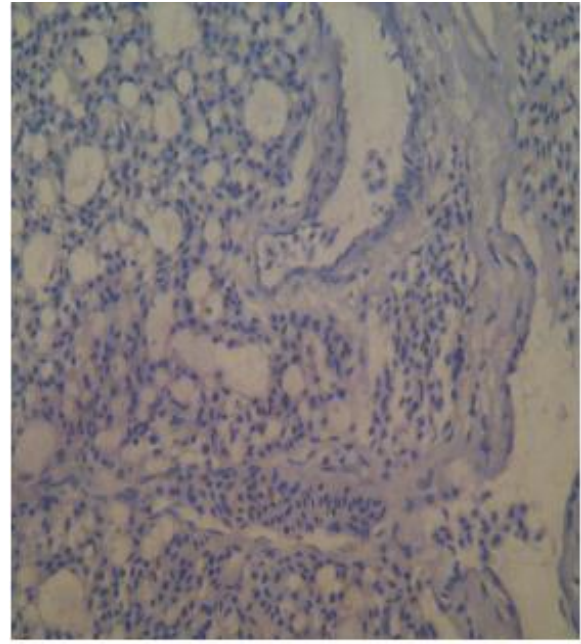


Plate Ib: Section of the lung of an adult Isa brown layer chicken associated with natural case of avian salmonellosis in Ogun State not incubated with *Salmonella* antibody (positive control) showing no immunoreactions (x 400; immunohistochemical reaction)

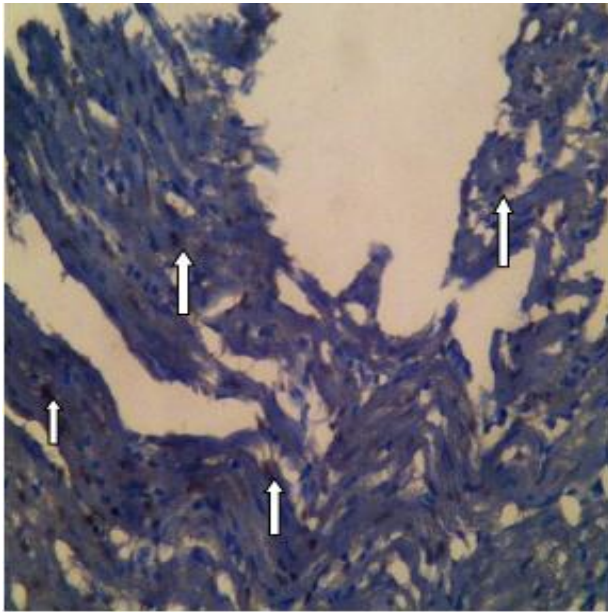


Plate IIa: Section of the heart of an adult Nera black layer chicken that died from natural case of avian salmonellosis in Lagos State showing immunoreactions in myocytes (arrows) (x 400; immunohistochemical reaction)

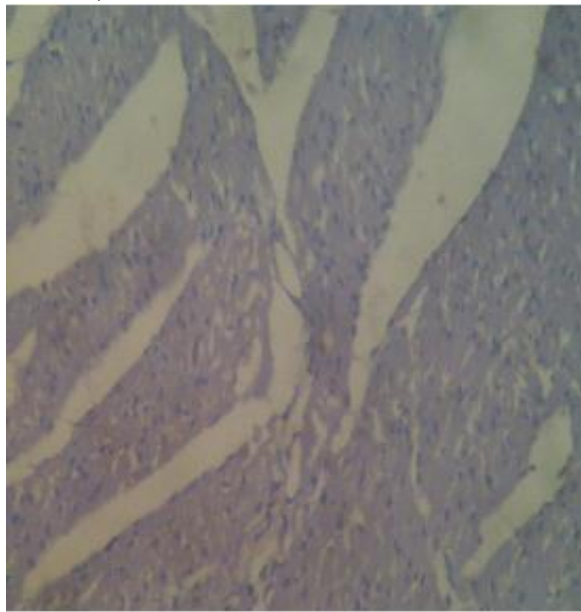


Plate IIb: Section of the heart of an adult Isa brown layer chicken associated with natural case of avian salmonellosis in Ogun State not incubated with *Salmonella* antibody (control) showing no immunoreactions (x 400; immunohistochemical reaction)

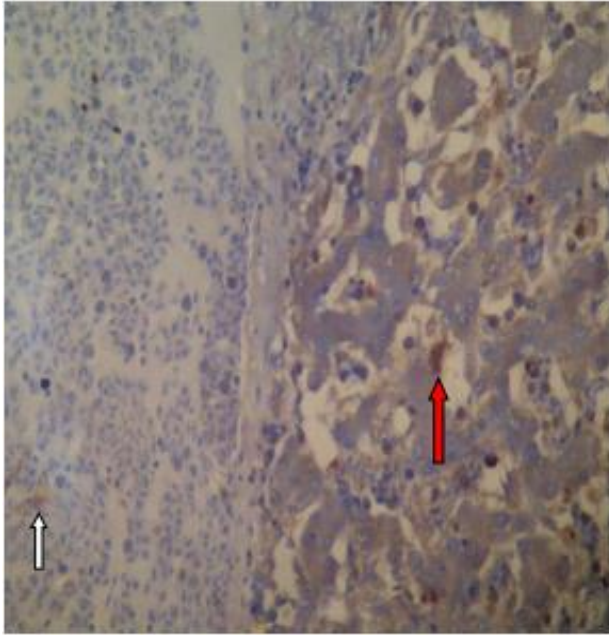


Plate IIIa: Section of the liver of an adult Isa brown chicken that died from a natural case of avian salmonellosis, showing immunoreactions to *Salmonella* antigen in the blood vessel (arrow), hepatocytes (red arrow) (x400; immunohistochemical reaction)

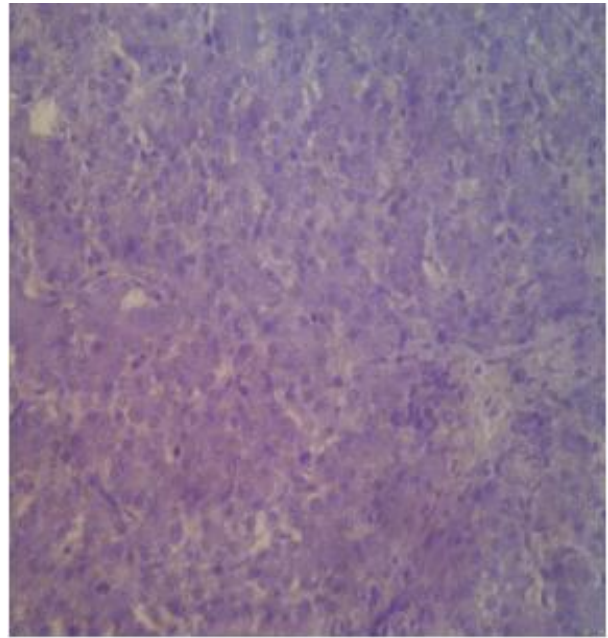


Plate IIIb: Section of the liver of an adult Isa brown layer chicken associated with natural case of avian salmonellosis in Ogun State not incubated with *Salmonella* antibody (control) showing no immunoreactions (x 400; immunohistochemical reaction)

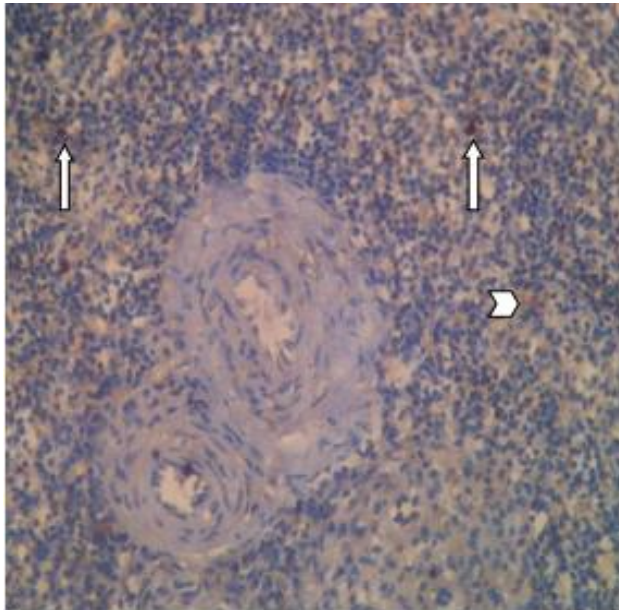


Plate IVa: Section of the spleen of an adult Nera black Cockerel chicken that died from natural case of avian salmonellosis in Oyo State showing strong immunoreaction in lymphocytes macrophages (arrows); but weak immunoreactivity in necrotic debris (arrow head)(x 400; immunohistochemical reaction)

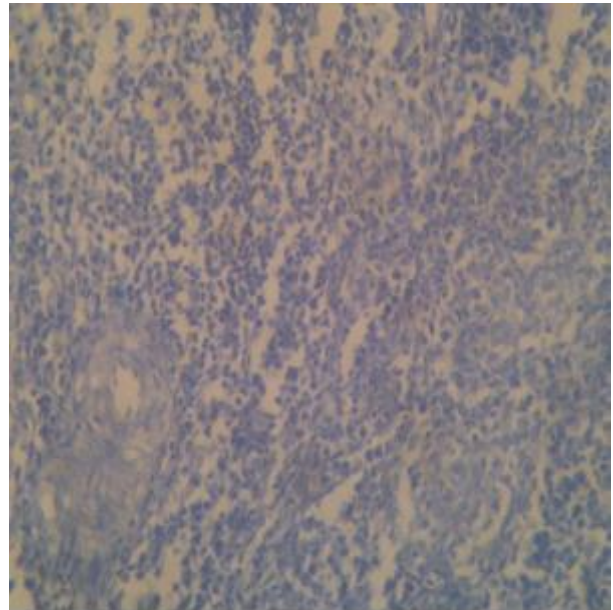


Plate IVb: Section of the spleen of an adult Isa brown layer chicken associated with natural case of avian salmonellosis in Ogun State not incubated with *Salmonella* antibody (control) showing no immunoreactions (x 400; immunohistochemical reaction)

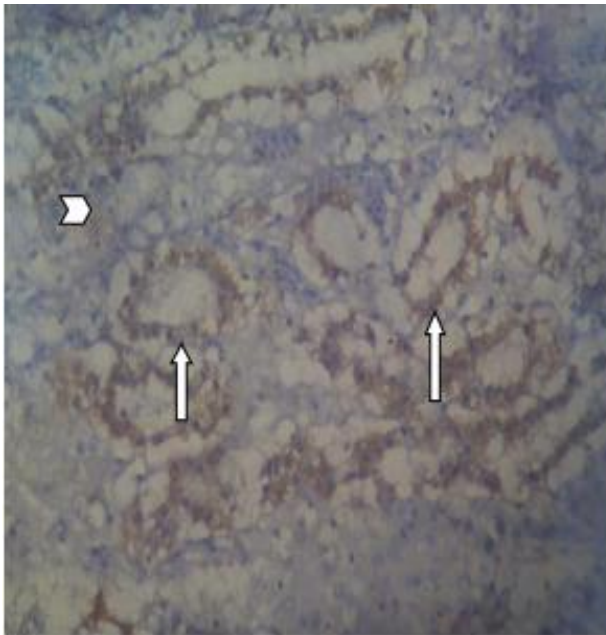


Plate Va: Section of the kidney of an adult Isa brown layer chicken that died from natural case of avian salmonellosis in Ogun State showing strong immunoreactions in tubular epithelial cells (arrows) but weak immunoreactions in necrotic debris (arrow heads) (x400; immunohistochemical reaction)

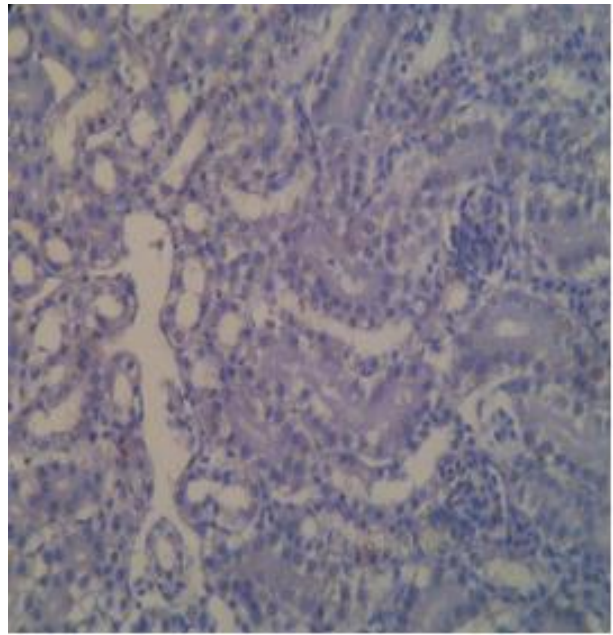


Plate Vb: Section of the kidney of an adult Isa brown layer chicken associated with natural case of avian salmonellosis in Ogun State not incubated with *Salmonella* antibody (control) showing no immunoreactions (x 400; immunohistochemical reaction)

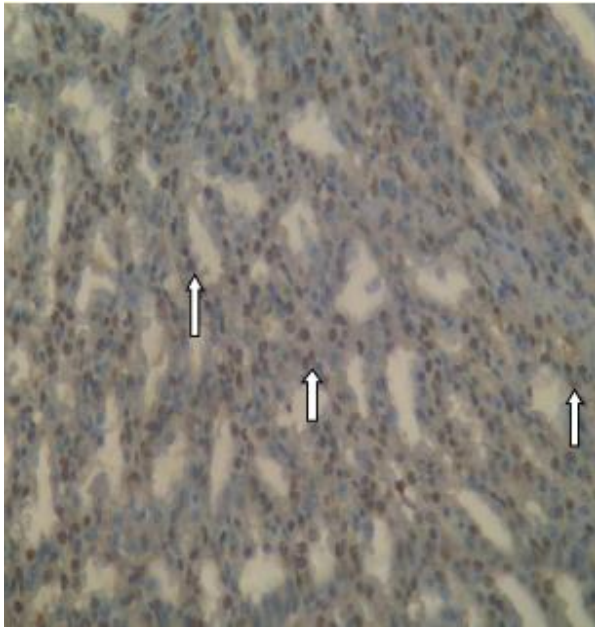


Plate VIa: Section of the proventriculus of an adult Isa brown layer chicken that died of natural case of avian salmonellosis in Ogun State showing severe immunoreactions in glandular (arrows) and mucosal columnar epithelial cells (x 400; immunohistochemical reaction)

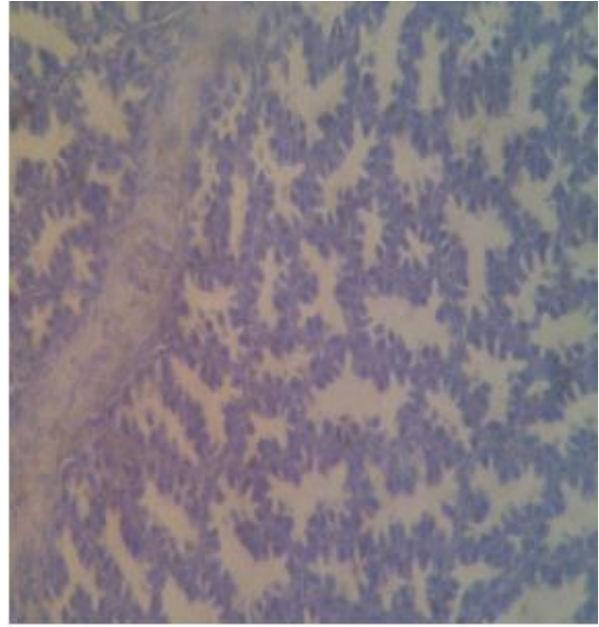


Plate VIb: Section of the proventriculus of an adult Isa brown layer chicken associated with natural case of avian salmonellosis in Ogun State not incubated with *Salmonella* antibody (control) showing no immunoreactions (x 400; immunohistochemical reaction)

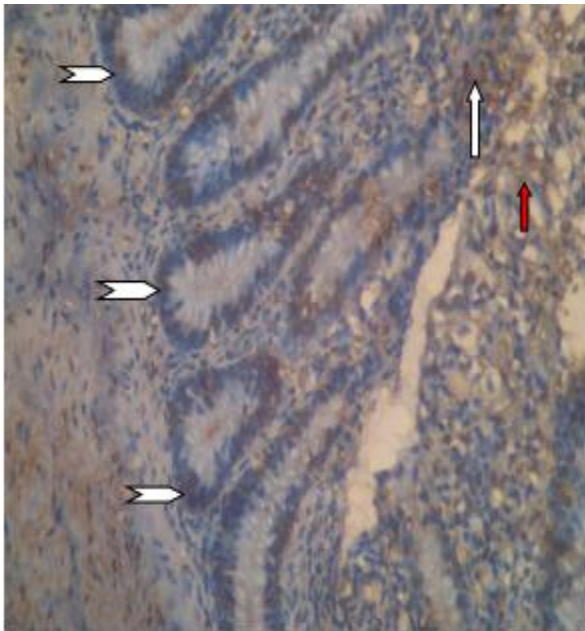


Plate VIIa: Section of the small intestine of an adult Isa brown broiler chicken that died from natural case of avian salmonellosis in Ogun State showing strong immunoreactions in the glandular (crypts of Lieberkuhn) (arrow heads) and mucosal columnar epithelial cells (white arrow), but weak immunoreactions in necrotic debris (red arrow) (x 400; immunohistochemical reaction)

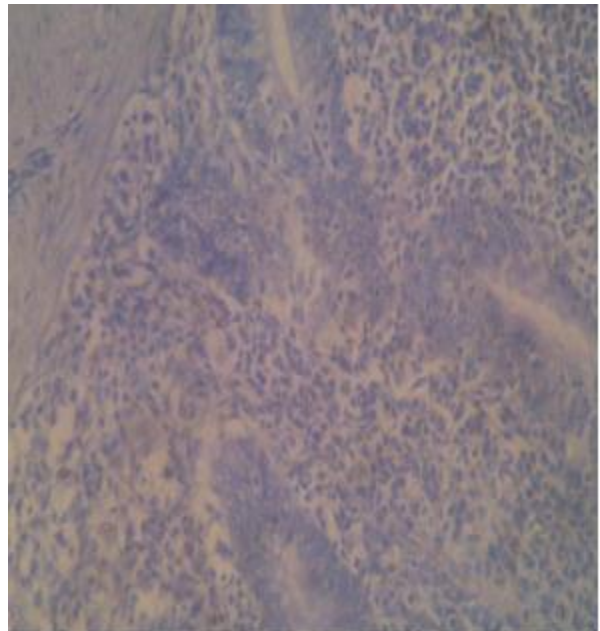


Plate VIIb: Section of the intestine of an adult Isa brown layer chicken associated with natural case of avian salmonellosis in Ogun State not incubated with *Salmonella* antibody (control) showing no immunoreactions (x 400; immunohistochemical reaction)

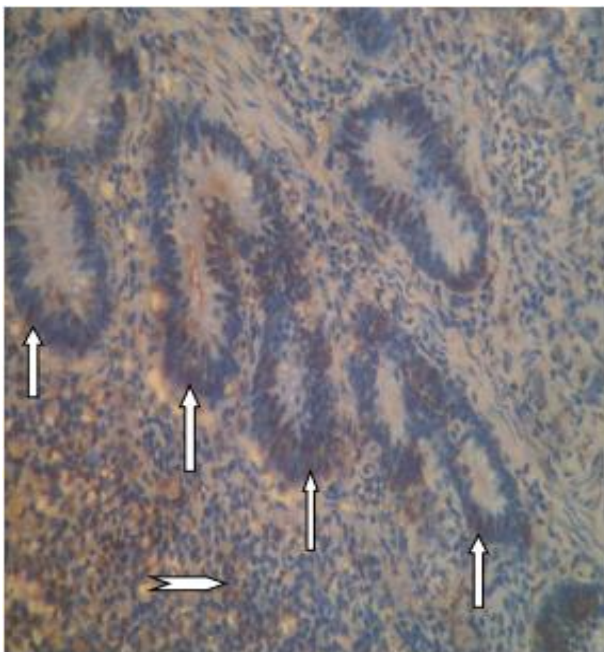


Plate VIIIa: Section of the caecum of an adult Isa brown layer chicken that died from natural case of avian salmonellosis in Ogun State showing strong immunoreactions in the glandular (crypts of Lieberkuhn) columnar epithelial cells (white arrows), but weak immunoreactions in necrotic debris (arrow head) (x 400; immunohistochemical reaction)

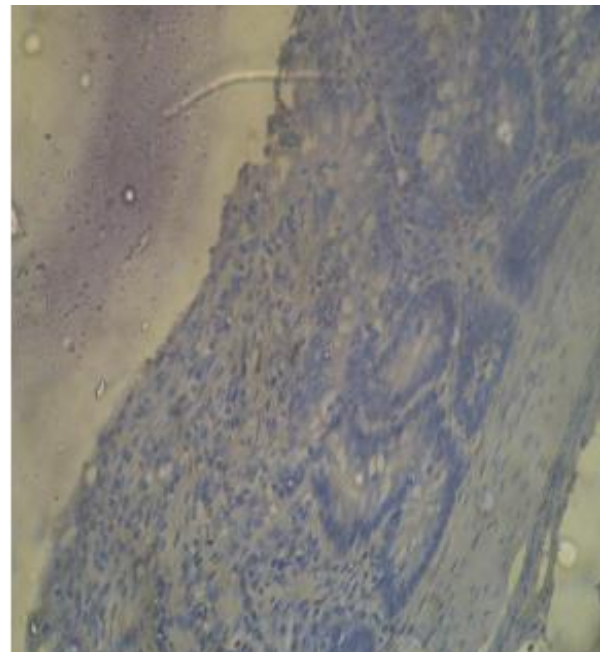


Plate VIIIb: Section of the caecum of an adult Isa brown layer chicken associated with natural case of avian salmonellosis in Ogun State not incubated with *Salmonella* antibody (control) showing no immunoreactions (x 400; immunohistochemical reaction)

Comparison of the sensitivity of bacteriology and immunohistochemical technique

Out of the 118 postmortem cases, 43 had clinical signs of lethargy, somnolence, yellowish diarrhea, and mortality of 40 to 80%, in which 36 presented with pathognomonic lesions of salmonellosis. *Salmonella* species were isolated in 31 (86.1%), representing 72.1% and 86.1% diagnosis by clinical signs and postmortem examination respectively. Fifty five isolates from twenty eight cases out of the 31 representing 90.3% tested positive biochemically, while PCR confirmed 37 isolates from 25 cases out of the 31(89.3%). On the other hand, immunohistochemical technique detected immunoreactions to *Salmonella* antigens in all the 36 suspected cases of salmonellosis that were tested, representing 100% sensitivity (Table 1).

Discussion

The clinical signs of somnolence, yellowish diarrhea and mortality as well as the gross lesions observed in the present study were suggestive for avian salmonellosis, as they agreed with the reports of various workers (Shivaprasad, 1997; Ogunleye *et al.*, 2006; Beyaz *et al.*, 2010; Majid *et al.*, 2010; Akhtar *et al.*, 2011; Abdu, 2014). However, confirmation of the diagnosis of avian salmonellosis is done by isolation and identification or by other reliable Laboratory methods such as immunohistochemistry (Ramos-vara *et al.*, 2008). In the present study, the 100% diagnosis by immunohistochemical technique was higher than the 86.1% by isolation and identification. This suggests that immunohistochemical technique is probably more sensitive than isolation and identification. It has been proven that immunohistochemical technique is a highly sensitive and specific diagnostic tool for infectious diseases (Henderson *et al.*, 1999; Ramos-vara *et al.*, 2008). It was also reported that immunohistochemical technique has advantage over isolation and identification, because it can detect the organism localized in the lesion even as the organism is dead, a process that is not possible bacteriologically (Desmidt, 1998; Ramos-vara *et al.*, 2008; Beyaz *et al.*, 2010). *Salmonella* species are intracellular organisms which can be found in the cytoplasm of different host cells (Henderson *et al.*, 1999; Shahinuzzaman *et al.*, 2011; Tunca *et al.*, 2012). In this present study, *Salmonella* antigens were detected in either the cytoplasm of epithelial cells, myocytes, hepatocytes, macrophages and lymphocytes or in blood vessels and interstitium, in

all the visceral organs that were tested. *Salmonella* species are known to survive phagocytosis and multiply in the cytoplasm of even phagocytes, thereby killing the infected cells (Okamura *et al.*, 2005; Hensel, 2006; Jones *et al.*, 2007). It was reported that in comparison with other diagnostic techniques, immunohistochemistry allows co-localization of an antigen within lesions, thereby dramatically increasing diagnostic accuracy (Ramos-vara *et al.*, 2008). Following oral ingestion, the pathogenesis of *Salmonella* infection start with the penetration of the mucosal epithelium of the small intestine by direct penetration of the epithelial cells lining the mucosae, where they interact with the columnar epithelial cells and microfold cell overlying the Peyer's patches (Henderson *et al.*, 1999). This interaction between *Salmonella* and the epithelium leads to the chemotactic attraction of inflammatory cells to the infection site where they phagocytose or become infected by the offending pathogen (Henderson *et al.*, 1999). *Salmonella* pathogen is known to survive intracellular environment and thereby providing accurate diagnosis by detection of the antigen in the cytoplasm of the affected host cells (Desmidt *et al.*, 1998; Henderson *et al.*, 1999; Hensel, 2006; Ramos-vara *et al.*, 2008; Tunca *et al.*, 2012). Bacteriological study showed that *Salmonella* organisms were also isolated in all the visceral organs, but with less frequency in comparison to the immunohistochemical detection of its antigens. Bacteriological results in this study were reliable since the bacterial isolates were confirmed using polymerase chain reaction which is a confirmatory method for characterizing *Salmonella* species (Szmolka *et al.*, 2006), and also used in the diagnosis of natural cases of avian salmonellosis.

In conclusion, immunohistochemical technique was found to be more sensitive in the diagnosis of avian salmonellosis than bacterial isolation and identification. We recommend that facilities in diagnostic laboratories in Nigeria should be upgraded to include immunohistochemical techniques, to serve as an adjunct to bacteriology in the diagnosis of avian salmonellosis and other infectious diseases.

Acknowledgement

We thank Mr PA Akinduti who was a laboratory technologist in the Department of Veterinary Microbiology, College of Veterinary Medicine, Federal University of Agriculture, Abeokuta, for his technical assistance in the microbiology work.

References

- AAAP American Association of Avian Pathologists (1998). *A Laboratory Manual for the Isolation and Identification of Avian Pathogens* (DE Swayne, JR Glisson, MW Jackwood, JE Pearson, WM Reed, editors), fourth edition, Pennsylvania. Pp 4-13.
- Abdu PA (2014). Pullorum Disease and Fowl Typhoid. In: *Manual of Important Poultry Diseases in Nigeria*. 5 and 6 Ventures, Jos, Plateau State, Nigeria. Pp 47-55.
- Agbaje M, Davies R, Oyekunle MA, Ojo OE, Fasina FO & Akinduti PA (2010). Observation on the occurrence and transmission of *Salmonella* Gallinarum in commercial poultry farms in Ogun State, south west Nigeria. *African Journal of Microbiology Research*, **4**(9): 796-800.
- Ajayi AO & Egbebi AO (2011). Antibiotic susceptibility of *Salmonella* Typhi and *Klebsiella pneumoniae* from poultry and local birds in Ado-Ekiti, Ekiti State, Nigeria. *Annal of Biological Research*, **2**(3): 431-437.
- Akhtar A, Hair-Bejo M, Omar AR, Zakaria Z & Khairani-Bejo S (2011). Pathogenicity of *Salmonella* Enteritidis phage type 3A and 35 after experimental infection of White-leg horn chicks. *The Journal of Animal and Plant Sciences*, **21**(4): 770-777.
- Beyaz L & Kutsal O (2003). Pathological and immunohistochemical studies in experimental *Salmonella* Gallinarum infection (fowl typhoid) in chickens. *Ankara Üniversitesi Veteriner Fakültesi Dergisi*, **50**(3): 219-227.
- Beyaz L, Atasever A, Aydin FK, Gumussou S & Abay S (2010). Pathological and clinical findings and tissue distribution of *Salmonella* Gallinarum infection in turkey poults. *Turkish Journal of Veterinary Animal Science*, **34**(2): 101-110.
- Cha S, Jang D, Kim S, Park J & Jang H (2008). Rapid detection and discrimination of the three *Salmonella* serotypes, S.Pullorum, S.Gallinarum and S.Enteritidis by PCR-RFLP of ITS and *fliC* genes. *Korean Journal of Poultry Science*, **35**(1): 9-13.
- Desmidt M, Ducatelle R & Haesebrouck F (1998). Immunohistochemical observation in the caeca of chickens infected with *Salmonella* Enteritidis phage type four. *Poultry Science*, **77**(1): 7374.
- El Tigani AA, Suleiman M, El Sanousi AG, Haytham EL, Beir Maha Fathelrahman, Nasir M T, Magzoub AM & Mohammed E H (2013). Bovine tuberculosis in South Darfur State, Sudan: An abattoir study based on microscopy and molecular detection methods. *Tropical Animal Health and Production*, **45**(2), 469-472.
- Fasure AK, Deji-Agboola AM & Akinyemi KO (2012). Antimicrobial resistance pattern and emerging flouroquinolone resistant *Salmonella* isolates from poultry and asymptomatic poultry workers. *African Journal of Microbiology Research*, **6**(11): 2610-2615.
- Galan JE, Ginocchio C & Costeas P (1992). Molecular and functional characterization of the *Salmonella* invasion gene *invA*: homology of *InvA* to members of a new protein family. *Journal of Bacteriology*. **174**(13):4338-4349.
- Henderson SC, Bounous DI & Lee DM (1999). Early events in the pathogenesis of avian salmonellosis. *Infection and Immunology* **67**(7): 3580-3588.
- Hensel M (2006). Pathogenicity Islands and Virulence of *Salmonella enterica*. In: *Salmonella Infections: Clinical, Immunological and Molecular Aspects* (P Mastroeni, D Maskell editors), Cambridge University Press, Cambridge, Pp 146-172.
- Jones MA, Hulme SD, Barrow PA & Wigley P (2007). The *Salmonella* pathogenicity Island 2 type 111 secretion systems play a major role in pathogenesis of systemic disease and gastrointestinal tract colonization of *Salmonella enteric* serovar Typhimurium in the chicken. *Avian Pathology*, **36**(3): 199-203.
- Kabir SM (2010). Avian colibacillosis and salmonellosis. A closer look at epidemiology, pathogenesis, diagnosis, control and public health concern. *International Journal of Environmental Research and Public Health*, **7**(1): 89-114.
- Majid A, Siddique M & Khan A (2010). Avian Salmonellosis: Gross and histopathological lesions. *Pakistani Veterinary Journal*, **20**(4): 21-40.
- Mbukio IJ, Raji MA, Ameh J, Saidu L, Musa WI & Abdu PA (2009). Prevalence and seasonality of fowl typhoid disease in Zaria-Kaduna State. *Nigeria Journal of Bacteriology Research*, **1**(1): 1-5.

- Muhammed M (2008). *The Role of Salmonella Species in Early Chick Mortality and the Application of Hazard Analysis Critical Control Point (HACCP) for Control*. PhD Thesis, Department of Veterinary Medicine, University of Maiduguri, Nigeria. Pp 1-145.
- Myers J (2004). Automated slide stainers for special stains, immunohistochemistry and *in site* hybridization: Review. *Medical Laboratory Observer*, **36**(1): 28-30.
- Ogunleye OA, Ajuwape ATP, Adetosoye AI & Ohore OG (2006). Pathogenicity of *Salmonella* Paratyphi A in pullets. *Revue d' Elevage et de Medicine Veterinaire des Pays Tropicaux*, **59**(1-4): 5-9.
- Okamura M, Lillehoj HS, Raybourne RB, Babu US, Heckert RA, Tani HM, Sasai K, Baba E & Lillehoj EP (2005). Differential responses of macrophages to *Salmonella enterica* serovars Enteritidis and Typhimurium. *Veterinary Immunology and Immunopathology*, **107**(3): 327-335.
- Okwori AEJ, Hashimu GA, Adefunji JA, Okeke IO & Junaid SA (2007). Serological survey of *Salmonella* Gallinarum antibody in chickens around Jos Plateau State, Nigeria. *Online Journal of Health and Allied Sciences*, **6**(2): 10-14.
- Rasmus-vara JA (2005). Technical Aspects of Immunohistochemistry. *Veterinary Pathology*, **42**(4): 405-426.
- Rasmus-vara JA, Kiupel M, baszler T, Bliven L, Brodersen B, Chelack B, Chelack B, Czub S, Del Piero F, Dial S, Ehrhart EJ, Graham T, Manning L, Paulsen D, Valli VE & West K (2008). American Association of Veterinary Laboratory Diagnosticians Subcommittee on Standardization of Immunohistochemistry. *Journal of Veterinary Diagnostic Investigation*, **20** (4): 393-413.
- Shahinuzzaman ABM, Saha AK, Mazumder AC, Das S, Sufian MA, Baki MA & Hossain MM (2011). Sequential pathological and immunohistochemical study of pullorum disease in experimentally infected chicks. *International Journal of Poultry Science*, **10**(5): 404-410.
- Shi SR, Cote RJ, Hawes D, Thu S, Shi Y, Young LL & Taylor CR (1999). Calcium-induced modification of protein conformation demonstrated by immunohistochemistry: what is the signal? *Journal of Histochemistry and Cytochemistry*, **47**(4): 463-464.
- Shivaprashad HL (1997). Pullorum Disease and Fowl Typhoid. In: *Diseases of Poultry* (BW Calnek, HJ Barnes, CW Beard, LR McDougald, YM Saif, editors), tenth edition. Iowa State University Press; Ames, IA, USA, Pp 82-96.
- Shivaprasad HL & Barrow P (2008). *Salmonella* infections. Pullorum Disease and Fowl typhoid. In: *Diseases of Poultry* (YM Saif, AM Fadly, JR Glisson, LR McDougald, LK Nolan, DE. Swayne, editors), twelve edition. Blackwell Publishing, Athens, Georgia, USA. Pp 302-345.
- Szmolka A, Kaszanyitzky E & Nagy B (2006). Improved diagnostic and real-time PCR in rapid screening for *Salmonella* in the poultry food chain. *Acta Veterinaria Hungarica*, **54**(3): 297-312.
- Tunca Toplu N, Kirkan S, Avci H, Aydogan A, Epikmen ET & Tekbiyik S. (2012). Pathomorphological, immunohistochemical and bacteriological findings in budgerigars (*Melopsittacus undulates*) naturally infected with *Salmonella* Gallinarum. *Avian Pathology*, **41**(2): 203-209.