



## Effect of a velogenic newcastle disease virus on body and organ weights of vaccinated Shika brown cocks

JS Rwuaan<sup>1</sup>, PI Rekwot<sup>2</sup> & BO Omontese<sup>1\*</sup>

<sup>1</sup>Department of Theriogenology and Production, Faculty of Veterinary Medicine,  
Ahmadu Bello University, Zaria, Nigeria

<sup>2</sup>Animal Reproduction Research Programme, National Animal Production Research Institute,  
Ahmadu Bello University, Zaria, Nigeria

\*Correspondence: Tel.: +2347030177310, E-mail: drbobwealth@yahoo.com

### Abstract

Newcastle disease virus (NDV) produces both gross and histopathologic changes in tissues and organs of infected birds. These lesions may cause increase or decrease in organ sizes especially lymphoid organs leading to immune suppression. Therefore, the effect of a velogenic NDV on the body and organ weights of vaccinated Shika brown (SB) cocks was studied. Forty SB cocks consisting of twenty control and twenty infected cocks were slaughtered at the age of thirty-two weeks after infection with a velogenic NDV. They were weighed before being sacrificed and their internal organs (liver, spleen, thymus, heart, bursa of Fabricius, brain and adrenal glands) were removed and weighed. Sections of these organs were taken and stored in Bouin's solution for 24 h and later sent for histology. The liver, spleen, thymus, heart and adrenal glands of the infected red SB cocks were heavier than those of the control red and white Shika brown cocks and infected white SB cocks. The weight of the spleen and brain of both the control and infected red and white cocks did not vary significantly ( $P>0.05$ ). The infected red cocks had heavier adrenal glands, heart and liver weight than the control red and infected white cocks. The spleen and brain body weight ratio was similar for both control and infected red and white cocks. The control white cocks had the least thymus body weight ratio. The control white cocks had a higher bursa body weight ratio than the infected red and white cocks and the control red cocks. Only one infected white cock showed perivascular infiltration of lymphocytes and foci of glial cells. The increase in organ weights was seen mostly in the infected red cocks. It is recommended that chickens be routinely vaccinated against Newcastle disease to prevent atrophy of the bursa of Fabricius.

**Keywords:** body weight, Newcastle disease, organ weight, Shika brown cocks, vaccination.

### Introduction

Growth and development of various organs of the domestic fowl have been of interest since the initial domestication of *Gallus gallus* (Thaxton, 2002). Newcastle disease (ND) is a highly contagious and the most dreaded disease of chickens, turkeys and many other birds caused by the Newcastle disease virus (Chuahan & Roy, 1998; Alexander & Jones, 2001; Ohore et al., 2002; Saidu et al., 2006; Hailu, 2012). Newcastle disease virus (NDV) causes severe and economically important disease in poultry around the globe (Munir et al., 2012). The velogenic NDV produces a severe disease with morbidity and mortality rates approaching 100% in unvaccinated

chickens (Alexander, 2001; Capua & Alexander, 2009). The virus affects organs such as lungs, intestine and central nervous system (Murphy et al., 1999). The gross lesions and the organs affected in birds infected with NDV are dependent on the strain and pathotype of the infecting virus in addition to the host and all the other factors that may affect the severity of the disease (Alexander, 1988). Although gross lesions may also be absent in ND infected birds, in the chicken hemorrhagic lesions are observed in the small intestines, proventriculus and ceca (Alexander, 1988). These lesions are markedly hemorrhagic and appear to result from necrosis on

the intestinal wall or lymphoid foci such as cecal tonsils (Parede & Young, 1990). Suppression of immune response of the hosts may be due to temporary or permanent damage to primary lymphoid organs (Nasser *et al.*, 2000). Generally gross lesions are not observed in the central nervous system of birds infected with NDV regardless of pathotype (McFerran & McCracken, 1988). A non-purulent encephalomyelitis with neuronal degeneration, foci of glial cells, perivascular infiltration of lymphocytes and proliferation of endothelial cells have been observed in the central nervous system (Omojola & Hanson, 1986; McFerran & McCracken, 1988). Small focal areas of necrosis in the liver and sometimes with hemorrhage in the gall bladder and heart have been reported (Ahmad *et al.*, 2007). Beard and Hanson (1984) reported regressive changes found in the lymphopoietic system with the disappearance of lymphoid tissue, presence of focal vacuolation and destruction of lymphocytes in the cortical areas and germinal centres of the spleen and thymus following NDV infection in chickens. Marked degeneration of the medullary region was reported in the bursa. The adult avian spleen has been characterized as predominantly a lymphocyte producing and an erythrocyte-destroying organ (Ahmad *et al.*, 2007). Central to the immune response is the normal embryonic development of thymic-derived lymphocytes (T-cells) and bursal or bone marrow derived lymphocytes (Reynolds & Maraqa, 2000). Gross pathologic changes are not usually present in the respiratory tract but when observed consist of hemorrhagic lesions and marked congestion of the trachea (Aldous & Alexander, 2001). In infected chickens and turkeys the ovarian follicles are often flaccid and degenerative. Hemorrhage and discolouration of the other reproductive organs may occur (Aldous & Alexander, 2001). The objective of this study was to evaluate the effect of the velogenic Kudu strain Newcastle disease virus on the body and organ weights of vaccinated SB cocks.

## Materials and methods

### Study location

This study was carried out at the Poultry Research Programme of the National Animal Production Research Institute (NAPRI), Shika, Zaria (11°N and 12°N, 7°E and 8°E), at an elevation of 650 m above sea level, in the Northern Guinea Savannah zone of Nigeria. An average annual maximum and minimum temperature of  $31.8 \pm 3.2^{\circ}\text{C}$  and  $18.0 \pm 3.7^{\circ}\text{C}$ , respectively characterize the climate of the area. The monthly average rainfall during the rainy season

(May – October) is  $148.1 \pm 68.4\text{mm}$  (69.2-231.9mm) while mean monthly relative humidity is  $71.1 \pm 9.7\%$ .

### Experimental cocks

Fifty 20 week-old SB cocks consisting of 28 white and 22 red strains were purchased from the National Animal Production Research Institute Shika and used for this study. The cocks had been routinely vaccinated against ND, using the National Veterinary Research Institute (NVRI) Vom produced vaccine before purchase.

### Management of cocks

The cocks were kept paired in cages and fed layers mash containing 18% crude protein, 95.6% dry matter, 17% crude fibre and 3% nitrogen *ad libitum*. Water was provided *ad libitum*. All the necessary screening and treatment for ecto, endo and hemoparasites were carried out. For a period of six weeks the cocks had their cloacal temperatures taken using a digital thermometer and were weighed weekly. The cocks were infected with 2 ml of  $10^{6.0}$  EID<sub>50</sub> of a velogenic 113 strain Kudu of Newcastle disease virus intranasally and orally after screening.

### Morphometric and biometric studies

Forty cocks consisting of 20 control and 20 infected SB cocks aged 32 weeks were used. They were weighed, slaughtered; their organs (liver, spleen, thymus, heart, bursae of fabricius, brain and adrenal gland) were dissected out and weighed. The organ body weight ratios were obtained by dividing the organ weights in grams by the body weight in grams and multiplying the products by 1000 as described by Krasselt (1986). Samples of these organs were fixed in bouins solution for 24 h after which a little cut section of the organ specimen with its label included in an enclosed metallic or plastic capsule was washed several times in tap water. The little cut section of the organ specimen enclosed in the metallic or plastic capsule with its label was passed through ascending grades of ethanol, starting from 70% to 80% to 95% and to 100%. The specimen spent 2 h each in the 70% and 80% alcohol and 1 hour each in the 95% and 100% alcohol. It was then transferred into a clearing agent (xylene) for 2 hours after which the complete specimen was then impregnated with wax. The capsule containing the tissue was transferred into molted wax and left for 2 – 4 h in an oven at  $50^{\circ}\text{C}$  -  $60^{\circ}\text{C}$ , after which the tissue was embedded. After embedding, the blocked tissue was mounted on a wooden or plastic block and left in the deep freezer to freeze. The blocked tissue was

then sectioned using the microtome into thin slides of tissue about 5 – 15 microns. The cut sections were spread out in a water bath and picked up with slides which had been smeared with adhesive, glycerine/albumin mixture. The picked up sections were allowed to dry in an oven set at 56°C for 1 h before they were stained.

## Results

Body and organ weights of infected and control SB cocks are summarized (Table 1). There was no significant difference ( $P>0.05$ ) in the body weights, liver, spleen and brain of the control and infected red and white SB cocks. The thymus and heart weight of the infected red cocks was significantly heavier ( $P<0.05$ ) than that of the control red and white cocks. The bursal weight of the control white cocks was heavier than that of the control red and infected red and white SB cocks. The infected red cocks had heavier adrenal glands than the control red and

infected red and white cocks (Table 1). Organ body weight ratios of infected and control SB cocks are summarized (Table 1). The infected red cocks had a higher liver body weight ratio than the control red and white cocks and infected white cocks. The spleen body weight ratio was the same for both control and infected red and white cocks. The control white cocks had the least thymus body weight ratio. The infected red cocks had the highest heart bodyweight ratio. The brain body weight ratio was the same for both control and infected red and white cocks. The control white cocks had a higher bursa body weight ratio than the infected red and white cocks and the control red cocks. The infected red cocks had the highest adrenal body weight ratio. Only one infected white Shika brown cock showed a brain lesion of non-purulent encephalomyelitis with neuronal degeneration, foci of glial cells and perivascular infiltration of lymphocytes (Figure 1).

**Table 1:** Organ body weight ratios of Shika brown cocks infected with a velogenic Newcastle disease virus

Parameter	RSB <sub>1</sub>	RSB <sub>2</sub>	WSB <sub>1</sub>	WSB <sub>2</sub>
Liver	11.00	13.00	10.00	12.00
Spleen	1.00	1.00	1.00	1.00
Thymus	2.00	2.00	1.00	2.00
Heart	5.00	7.00	5.00	6.00
Brain	1.00	1.00	1.00	1.00
Bursa	0.20	0.24	0.30	0.28
Adrenal gland	0.16	0.24	0.14	0.18

### Key

RSB<sub>1</sub> = Control red Shika brown cocks

RSB<sub>2</sub> = Infected red Shika brown cocks

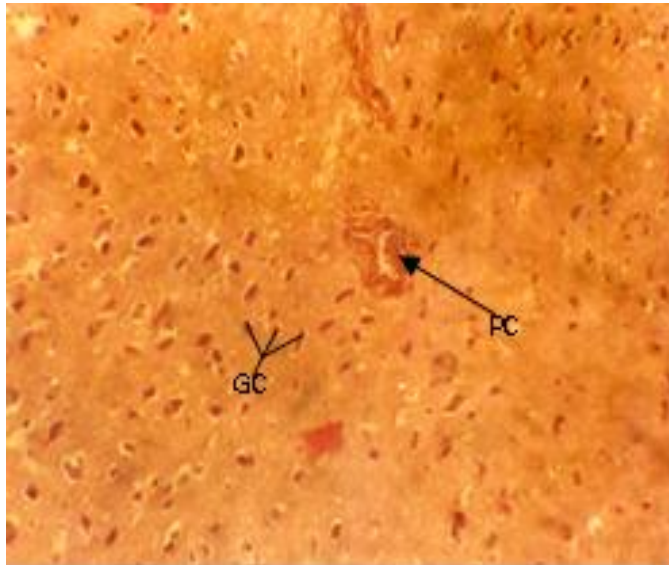
WSB<sub>1</sub> = Control white Shika brown cocks

WSB<sub>2</sub> = Infected white Shika brown cocks

## Discussion

In the present study the heart weights of the infected red cocks differed significantly from those of the control red and white cocks and this disagrees with work of Panwitz & Berg (1998) who reported non-significant heart weight changes in turkeys. Rajpal *et al.* (1992), Rajpal *et al.* (1993) and Das *et al.* (1997) found that the average gross weight of the duck's heart was heavier than that of the domestic fowl. There was an increase in the size of liver of the infected Red and White SB cocks in this work. This corroborates the findings of Lucy *et al.* (2012) who isolated Newcastle disease virus from the liver and kidney of infected

ducks indicating viral excretion from these organs. The increase The bursa of Fabricius of the cocks in this study decreased in weight contrary to the findings of Dafwang *et al.* (1985) and Dafwang, (1996) who reported that chicks fed antibiotics had heavier bursae. However, it is contrary to the report of Fulton *et al.* (1996) who reported cyclophosphamide induced bursal atrophy in NDV infected chicks. The bursae controls immunity, heavier bursae translate to enhanced immunity for the cocks. The 0.5 gm of the bursae of infected SB cock recorded



**Figure 1:** Perivascular cuffing and gliosis in white Shika brown infected cock

PC = Perivascular cuffing

GC = Glial cells

in this study is higher than the 0.49 gm reported by Ahmad *et al.* (2007) in ND vaccinated broilers treated with cyclophosphamide. The decrease seen in the weight of the bursa of Fabricius is an indication that the velogenic Newcastle disease virus used in this study may cause immunosuppression in infected cocks (Reynolds & Maraqa, 2000) and this corroborates the findings of Okoye *et al.* (2000) who reported atrophy of the bursa of Fabricius in Newcastle disease infected chickens. Relative heart weight increased significantly in the infected red cocks used in this work. Perivascular cuffing seen in this work agrees with that reported by Beard & Hanson (1984). Alexander *et al.* (1985) reported a non-purulent encephalomyelitis with neuronal degeneration foci of glial cells and perivascular infiltration of lymphocytes in Newcastle disease infected chickens. The implication of the lesions seen

in the brain of ND virus infected vaccinated cocks is that the virus could cause brain lesions without death and nervous signs and such lesions may last up to 6 weeks post infection. The SB cocks used in this study were previously vaccinated with Newcastle disease virus vaccine. Their subsequent challenge with the velogenic Newcastle disease virus led to the production of more antibodies against the velogenic Newcastle disease virus. It can be concluded from the study that the reduction in the weight of the bursa in the infected red and white SB cocks may affect their immune status thereby reducing their protection from the velogenic Newcastle disease virus. Owing to the devastating effect of NDV on poultry production, it is recommended that poultry farmers should routinely and adequately vaccinate their chickens to protect them from Newcastle disease infection.

## References

- Ahmad MW, Abbas MA, Muneer IH & Hanif A (2007). Immunomodulatory effects of flumequine and enrofloxacin on Newcastle disease virus vaccinated broiler chicks. *Pakistan Journal of Life and Social Sciences*, **5** (1-2): 24-29.
- Aldous EW & Alexander DJ (2001). Technical review: Detection and differentiation of Newcastle disease virus (avian paramyxovirus type 1). *Avian Pathology*, **30** (2): 117–129.
- Alexander DJ (1988). Newcastle disease. Methods of spread. In: D.J. Alexander (editor). *Newcastle Disease*, Kulwer Academic Publishers, Boston, MA. Pp. 256-272.

- Alexander DJ (2001). Newcastle disease – The Gordon Memorial Lecture. *British Poultry Science*, **42** (1): 5–22.
- Alexander DJ & Jones RC (2001). *Paramyxoviridae*. In: *Poultry Disease, 5th edition*. (F Jordan, M Pattison, D Alexander & T Faragher editors). WB Saunders, London. Pp 257-267.
- Alexander DJ, Wilson GWC, Russell PH, Lister SA & Pearsons G (1985). Newcastle disease outbreaks in fowl in Great Britain during 1984. *Veterinary Record*, **117** (17): 429-439.
- Beard CW & Hanson RP (1984). *Newcastle Disease*. In: *Diseases of Poultry 8<sup>th</sup> Edition*. (MS Hofstad, HJ Barnes, BW Calneck, WM Reid & HW Yorder, editors). Iowa State University Press, Ames, Iowa. Pp 452-470.
- Capua I & Alexander DJ (2009). Avian influenza infection in birds: A challenge and opportunity for the poultry veterinarian. *Poultry Science*, **88** (4): 842–846.
- Chuahan HV & Roy SY (1998). *Poultry Disease Diagnosis, Prevention and Control*. (7th edition). WB Saunders, India, Pp 58-429.
- Dafwang II, Cook ME, Sunde ML & Bird HR (1985). Bursal, intestinal and spleen weights and antibody response of chicks fed sub-therapeutic levels of dietary antibiotics. *Poultry Science*, **64** (4): 634-639.
- Dafwang II, Sunde ML, Cook ME, Schaefer DM, Ricke SC & Pringle DJ. (1996). Effect of antibiotics and water quality on the growth, intestinal characteristics and bacterial populations of broiler chicks. *Nigerian Journal of Animal Production*, **23** (2): 116-123.
- Das RK, Mishira UK & Mishiro SC (1997). Gross and biometrical observations on the heart of Indian duck (*Anas platynchos*). *Indian Journal of Poultry Science*, **32** (1): 93-96.
- Fulton RM, Reed WM, Thacter HL & Denicola DB (1996). Cyclophosphamide cytoxan R) Induced hematogenic alterations in specific pathogen-free chickens. *Avian diseases*, **40** (3):1-12.
- Hailu, M (2012). Review on major viral diseases of chickens reported in Ethiopia. *Journal of Infectious Diseases and Immunity*, **4** (1):1-9.
- Krasselt MM (1986). Comparative study on Delvax<sup>®</sup> Gumboro and on the efficacy of Delvax<sup>®</sup> Newcastle disease clone L 258. *Animal Health Newsletter*, November Issue. Pp 9.
- Lucy WN, Phillip NN, Lilly CB, Paul GM, &Uswege MM (2012). Effect of Immunosuppression on Newcastle Disease Virus Persistence in Ducks with Different Immune Status. *Veterinary Science*, **12**, doi:10.5402/2012/253809.
- McFerran JB & McCracken RM (1988). Newcastle disease. In: *Newcastle Disease* (DJ Alexander editor). Kluwer Academic Publishers, Boston, MA. Pp. 161-183.
- Munir M, Abbas M, Khan MT, Zohari S & Berg M (2012). Genomic and biological characterization of a velogenic Newcastle disease virus isolated from a healthy backyard poultry flock in 2010. *Virology Journal*, **9**:46
- Murphy FA, Gibbs EPJ, Hozinek MC, Studdert MJ (1999). *Veterinary Virology, 3rd edition*. London: Academic press. Pp 405-409.
- Nasser M, Lohr JE, Mebratu GT, Zessin KH, Baumann MPO & Ademe Z (2000). Oral Newcastle disease vaccination trials in Ethiopia. *Avian Pathology*, **29** (1):27–34.
- Ohore OG, Ozegebe PC, Emikpe BO & Okojie VE (2002). Survey of antibodies to Newcastle disease virus in apparently healthy adult Nigerian indigenous chickens (*Gallus domesticus*) in Ibadan using ELISA. *African Journal of Clinical & Experimental Microbiology*, **3** (1): 38-40.
- Okoye JOA, Agu AO, Chineme CN & Echeonwu GON (2000). Pathological characterization in chickens of a velogenic Newcastle disease virus isolated from guinea fowl. *Revue d'elevage et de médecine veterinaire des Pays Tropicaux*, **53** (40): 325-330.
- Omojola E & Hanson RP (1986). Collection of diagnostic specimens from animals in remote areas. *World Animal Reviews*, **60**:38-40.
- Panwitz G & Berg R (1998). Morphometric studies into the myocardium, kidney and adrenal gland of turkeys (fattening hybrid strain Big-6). *Archives ein Geflugelkunde*, **62** (5): 229-233.
- Parede L & Young PL (1990). The pathogenesis of velogenic Newcastle disease virus infection of chickens of different ages and different levels of immunity. *Avian Diseases*, **34** (4):803-808.
- Rajpal DK, Shrivastava AM, Malik MR Laluja JS & Parmar MI (1992). Studies on circumference and cross sectional area of ventricles in heart of pre and post hatch fowl. *Indian Journal of Animal Science*, **62** (12):1161-1166.

- Rajpal DK, Shrivastava AM, Malic MR, Taluja JS & Parmar MI (1993). Topographic and morphometric Studies on heart of fowl. *Indian Journal of Animal Science*, 63(2): 159-161.
- Reynolds DL & Maraqa AD (2000). Protective immunity against Newcastle disease: The role of cell-mediated immunity. *Avian Diseases*, **44** (1):145—154.
- Saidu L, Abdu, PA Tekdek LB, Umoh JU, Usman M & Oladele SB (2006). Newcastle disease in Nigeria. *Nigerian Veterinary Journal*, **27** (2): 23-32.
- Thaxton JP (2002). Heart growth in broilers. *British Poultry Science*, **43** (1): 24-27.